

VASCA Magazine

Living with Vascular Anomalies

Introduction

Vascular Anomalies

Genetics


Research

Treatments and Medication

Quality of Life



European
Patient
Advocacy
Group



Imprint

>> VASCA Magazine

Patient Advocates' Magazine of the VASCA-WG (VASCERN)
Edition 2 | 2024

Digital edition (PDF) as well as print editions organised
in different countries by authorised publishers

>> Editors:

HEVAS
Federal Association of Congenital Vascular Malformations
CMTC-OVM
LGD Alliance Europe
VASCAPA
Andlinfa
AVMinority

>> Editorial office:

Maria Barea
Caroline van den Bosch
Petra Borgards

>> Contact:

HEVAS, Stationsweg 6B, 3862 CG Nijkerk, Netherlands
Federal Association of Congenital Vascular Malformations,
Blötter Weg 85, 45478 Mülheim an der Ruhr, Germany
CMTC-OVM, Koninksweg 1, 7064 KH, Silvolde, Netherlands
LGD Alliance Europe, info@ldga.eu
VASCAPA a.s.b.l., Avenue Leo Errera 8, 1180 Uccle, Belgium
andLINFA, Av. Miguel Bombarda Nr. 21 2º Dt. 1050-161,
Lisboa, Portugal
AVMinority, Na Výsluní 2117, 289 22 Lysá nad Labem, Czechia

>> Concept & Layout:

Kathrin Sachse | KS kreativ & sozial (Germany)
www.creative-and-social.eu



Editorial office (from left to right see above)

Source: Maria Barea

W Connected, even the
weak become powerful.

Friedrich Schiller



HEVAS
(Netherlands)

info@hevas.eu
www.hevas.eu



Federal Association of Congenital
Vascular Malformations
(Germany)

info@angiodysplasie.de
www.angiodysplasie.de



CMTC-OVM
(Netherlands)

president@cmtc.nl
www.cmtc.nl/en



LGD Alliance Europe
(The Netherlands)

info@lgda.eu
www.lgda.eu



VASCAPA
(Belgium)

info@vascapa.org
www.vascapa.org/en/



AVMinority
(Czech Republic)

info@avminority.cz
www.avminority.cz



AndLINFA
(Portugal)

info@andlinfa.pt
www.andlinfa.pt

Editorial

In 2020 an idea was born: the first patient organisation (PO) based European magazine aimed at non-specialised doctors and other health care providers, and people affected by vascular anomalies. It set out to spread knowledge of vascular anomalies and empower patients.

The first 72-page digital edition was published in April 2021 through VASCERN's and the PO's websites and social media. Printed copies and a flyer were also used as promotional tools. It covered the following areas:

- State of the art scientific articles written in plain language and complemented by testimonials of affected people or caregivers.
- The work & services of VASCA patient organisations.
- What the ERNs, VASCERN, and VASCA are, and the work they do to achieve better care for patients and their key projects.

The articles were written by VASCA (or related) clinicians, members of the patient organisations and VASCERN's coordination team. An external graphic designer created the layout and the project received EU-funding.

The magazine was broadly recognised as valuable by doctors and patients. It was presented as an example of collaboration at EURORDIS's (Rare Diseases Europe) ePAG Annual Meeting "Inspiring Collaboration and Fostering Partnership in the ERNs" (2021), at ECRD2022 (European Conference on Rare Diseases and Orphan Products), shared at 2022 ISSVA (International Society for the Study of Vascular Anomalies) International congress and in the "The Orphanet Journal of Rare Diseases (OJRD)" (2022).

VASCA Magazine is a lighthouse project of cooperation and good partnership between patient organisations' representatives and clinicians of VASCERN-VASCA.

Due to its success, we decided to continue and publish the magazine on a regular basis. Today we proudly present the second edition.

The first VASCA Magazine is available at VASCERN's website:

🔗 <https://vascern.eu/app/uploads/2023/06/VASCA-Magazine-Edition-1.pdf>



In this new issue you will find several articles describing vascular anomalies, their genetics, research, current therapies, as well as news from the VASCERN team and EURORDIS. You will also find testimonials of patients from across Europe living with vascular anomalies, describing their lives and challenges they face. Additionally, we have the pleasure to introduce and welcome two new patient organisations (and their patient representatives), members of the VASCA team:

- Silvie Slivová - AVMinority from the Czech Republic and
- Carminda Ramos - andLINFA from Portugal

We hope that this new issue will once again provide valuable information for both doctors and patients, as well as insights into the work of VASCERN.

The editorial team: Maria Barea (Belgium), Petra Borgards (Germany) and Caroline van den Bosch (The Netherlands)

Editorial's note:

The copyright in all articles published in VASCA Magazine is reserved and may not be reproduced without permission. Neither the publishers nor the editors necessarily agree with the views expressed in the magazine.

This magazine and all its content is intended for information purposes only. It is not intended for medical purposes and it should never replace medical advice. In case of any question or doubt, please contact your treating doctor or specialist.

Table of Contents

INTRODUCTION

Patient organisations represented so far	5
AVMinority Newly joined as a patient organisation to VASCA	6
andLINFA Associação Nacional de Doentes Linfáticos Newly joined as a patient organisation to VASCA.....	7
SPOTLIGHT Silvie Slívová responds to questions about her work, her personal motivations and her wishes and hopes for the 'ERN' project Silvie Slívová (AVMinority)	8
SPOTLIGHT Carminda Alves Gonçalves answers questions about her work, her personal motivations, wishes and hopes for the 'ERN' project Carminda Alves Gonçalves (andLINFA)	9
VASCERN: Achievements in the First 5 Years Prof. Guillaume Jondeau, Julie Hallac, Natasha Barr, Yaël Glin, Ibrahim Donmez, Treasure Udechukwu, Gloria Somalo Barranco	10
Latest Changes in VASCERN Prof. Guillaume Jondeau, Julie Hallac, Natasha Barr, Yaël Glin, Ibrahim Donmez, Treasure Udechukwu, Gloria Somalo Barranco	12
News from the VASCA WG Julie Hallac, Natasha Barr, Yaël Glin, Ibrahim Donmez, Treasure Udechukwu, Gloria Somalo Barranco, Prof. Guillaume Jondeau	13
Introduction of the New VASCA WG Centres	14
ERN Academy Moodle Platform Yaël Glin, Julie Hallac, Prof. Guillaume Jondeau	18
CPMS 2.0: A User-Friendly Solution for Cross-Border Clinical Discussions Prof. Leo Schultze Kool, MD, PhD	19
EURORDIS' Role in Fostering Patient-Clinician Partnership in the European Reference Networks Ines Hernando	20

VASCULAR ANOMALIES

Progression of Vascular Malformations, Factors of Influence Carine JM van der Vleuten, MD, PhD	22
Complex Lymphatic Anomalies Pär Gerwins, MD, PhD	28
TESTIMONIAL A Lymphatic Malformation Made Erwin Become a Tech Savvy Erwin Oudshoorn (HEVAS)	32

Diagnostics and Management of Peripheral Arteriovenous Malformations

Dr. Annouk Bisdorff Bresson, MD, Dr. Rune Andersen, MD	33
---	----

TESTIMONIAL Life and Choices with an Arteriovenous Malformation

Coraline	38
----------------	----

Port Wine Stains/ Capillary Malformation and Sturge-Weber Syndrome: Frequently Asked Questions Regarding Laser Treatment

Eulalia Baselga, MD, PhD	40
--------------------------------	----

TESTIMONIAL Tessa has Sturge-Weber Syndrome

Brenda Kluijver (HEVAS)	43
-------------------------------	----

TESTIMONIAL Anouk is Living with PTEN Hamartoma Tumour Syndrome (Cowden Syndrome)

Diana de Veld	45
---------------------	----

Congresses and Meetings on Vascular Anomalies ...

47

Highlights from ISSVA 2022

Bas Verhoeven, MD	51
-------------------------	----

GENETICS

The Research Work Performed on Vascular Anomalies at the Laboratory of Humans Genetics of the de Duve Institute

Prof. Miikka Vikkula, MD, PhD, Francisca Voermans, drs. ir	53
---	----

RESEARCH

Sirolimus in Slow-flow Vascular Anomalies: a Current Overview

Emmanuel Seront, MD, PhD, An Van Damme, MD, PhD, Miikka Vikkula, MD, PhD, Laurence Boon, MD, PhD	57
---	----

TREATMENTS AND MEDICATION

TESTIMONIAL A Patient's Experience with AVM Treatment in the Czech Republic

Silvie Slívová	61
----------------------	----

Anxiety and Pain Management in Children During a Medical Procedure

Dr. Lilian Vermeer	62
--------------------------	----

EXTRAS

VASCA-WG Healthcare Providers (HCP) Full members	63
--	----



Patient organisations represented so far

 <p>HEVAS (The Netherlands)</p> <p>○ c.vd.bosch@hevas.eu ○ www.hevas.eu</p>	 <p>Caroline van den Bosch</p>	<p>Website</p>  <p>Facebook</p> 	<p>Disease profiles: All types of vascular malformations, vascular tumours, syndromes and PROS.</p> <p>Foundation year: 2007</p> <p>Language(s): Dutch (also English and German for communication)</p>
 <p>Federal Association of Congenital Vascular Malformations (Germany)</p> <p>○ borgards@angiodyplasie.de ○ www.angiodyplasie.de</p>	 <p>Petra Borgards</p>	<p>Website</p>  <p>Youtube</p> 	<p>Disease profiles: All types of vascular malformations including cerebral malformations and syndromes.</p> <p>Foundation year: 2006</p> <p>Languages: German, English</p>
 <p>CMTC-OVM (The Netherlands)</p> <p>○ president@cmtc.nl ○ www.cmtc.nl/en</p>	 <p>Lex van der Heijden</p>	<p>Website</p>  <p>Social media</p> 	<p>Disease profiles: Both identified as well as unidentified vascular malformations.</p> <p>Foundation year: 1997</p> <p>CMTC-OVM is based in the Netherlands and is a world-wide non-profit patient organisation.</p> <p>Language(s): Dutch, English and German</p>
 <p>LGD Alliance Europe (The Netherlands)</p> <p>○ mary@lgda.eu ○ www.lgda.eu</p>	 <p>Mary Keniry</p>	<p>Website</p>  <p>Facebook</p> 	<p>Disease profiles: All types of complex lymphatic anomalies (CLAs), including GSD, KLA, GLA and CCLA.</p> <p>Foundation year: 2010</p> <p>The LGD Alliance Europe is a European organisation.</p> <p>Languages: English, Dutch, Spanish, Italian and several other European languages</p>
 <p>VASCAPA (Belgium)</p> <p>○ president@vascapa.org ○ www.vascapa.org</p>	 <p>Maria Barea</p>	<p>Website</p>  <p>Facebook</p> 	<p>Disease profiles: All types of vascular anomalies including syndromes.</p> <p>Foundation year: 2012</p> <p>Language(s): French and Dutch (also English, German, Italian, Arabic and Spanish)</p>

AVMinority

Newly joined as a patient organisation to VASCA



Disease profiles:

Arteriovenous malformation (AVM) of head and neck.

Country: Czech Republic

Foundation year: 2011

Language(s): Czech (and English for communication)

Mission:

We strive to improve the quality of life for people with arteriovenous malformations (AVM) of the head and neck through counseling, self-help activities and sharing the experience of our patients. We also try to raise awareness of the disease among the public and professionals through our website, social media and other promotional activities.

By choosing the name AVMinority we want to stress the rare nature of the head and neck AVMs, which, despite their low incidence, deserve equal attention as other severe disorders.

Core activities:

OUTREACH ACTIVITIES

We focus on informing the professional and lay public about head and neck AVMs, their current treatment options, and other complex issues related to this disease group through educational activities.

PROVIDING OPPORTUNITIES

We bring together patients with AVMs of the head and neck to exchange experience, share thoughts and emotions and provide mutual psychological support.

INFORMATION

We share expert information about AVM of head and neck and up-to-date developments in diagnosis and treatment.

IMPROVING HEALTHCARE

Our consulting services are dedicated to assisting patients in obtaining accurate diagnoses, accessing specialized healthcare in the Czech Republic and other EU countries, as well as liaising with doctors with expertise in the area.



from left to right: Radka Švecová, Silvie Slívová, Barbora Slívová and Jakub Slíva

Source: AVMinority

COLLABORATION

We support science and research, participate in working groups for rare diseases and cooperate with other Czech and European professional organizations for rare diseases (CAVO, EURORDIS, VASCERN, Orphanet, etc.).

Chairperson & Contact person VASCA:

Silvie Slívová

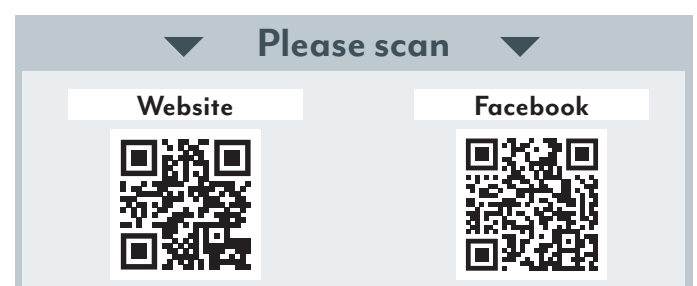
✉ silvie.slivova@avminority.cz

Social Media:

✉ www.facebook.com/AVMinority

Website:

✉ www.avminority.cz



andLINFA | Associação Nacional de Doentes Linfáticos

Newly joined as a patient organisation to VASCA



Disease profiles:

We cover rare vascular diseases (our working groups currently includes vascular anomalies, primary lymphedema and vascular Ehlers-Danlos Syndrome), but also secondary lymphedema and lipedema.

Country: Portugal

Foundation year: 2015

Language(s): Portuguese

Main goals:

We are a patient organisation that aims to improve knowledge about rare vascular diseases throughout Portugal. The various actions we develop are aimed at providing the patient, family, or carers with a multidisciplinary network, where answers can

be found to improve support and quality care. We also want to promote greater visibility and acceptance of these diseases among the community.

Core activities:

- We work to increase awareness of the different vascular diseases.
- We promote meetings, seminars and congresses with invited specialists from Portugal.
- We aim to influence the Health Policy.
- We work in networks with our stakeholders to find answers.
- We collaborate in research.
- We provide physical activity -namely Nordic Walking- with the technical support of a Sports University.
- We establish links with patients and their families.

Chairperson:

Manuela Lourenço Marques

○ info@andlinfa.pt

Contact person VASCA:

Carmina Alves Gonçalves

○ mindaramos@hotmail.com

Website:

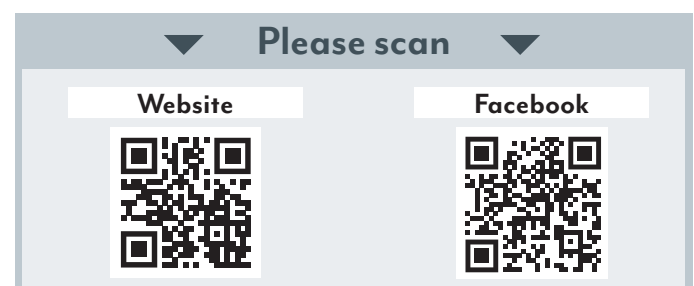○ www.andlinfa.pt

Social media:

- www.facebook.com/andLINFA
- https://instagram.com/andlinfa_portugal
- <https://linkedin.com/company/andlinfa-associacao-de-doentes-linfaticos-portugal/>
- <https://twitter.com/andlinfa>



ePAG member Carminda Alves Gonçalves





Silvie Slívová responds to questions about her work, her personal motivations and her wishes and hopes for the 'ERN' project

Silvie Slívová (AVMinority)

Can you tell us something about the reasons for your commitment?

I developed first signs of my disease at the age of 16. The doctors initially diagnosed me with a hemangioma. Eventually after 5 years, when I started treatment in Zurich (Switzerland), the diagnosis was changed to AVM, when I suddenly started bleeding massively from my mouth (from the gum around my tooth).

I lived under daily life-threatening circumstances for 22 years until successful treatment in the USA in 2018.

I narrowly escaped death several times. I always arranged treatment abroad on my own initiative and had to find most of the information about my disease on the internet or previously in medical libraries. The lack of information even led me to pursue a medical degree at medical school.

I often felt helpless and lonely, I had no contact and did not even know about other patients with AVM (at the beginning I even thought I was the only one in the world).

All this eventually led me to start a patient organisation with the aim of spreading information and my experience about AVM among doctors and the public, so that no one in the Czech Republic would have to go through such a long and complicated path to treatment as I did.

How did you become involved in the VASCERN project?

Contact with the VASCERN and VASCA teams was facilitated by CAVO (Czech Association for Rare Diseases), who invited us to join the first VASCERN ePAG-Community Meet & Greet - a zoom conference organised by VASCERN's patient advocates - at the beginning of 2021.

How do you as an ePAG patient advocate participate in the activities of VASCERN?

As an ePAG Patient Advocate, I am new to this role, and I learn all the ins and outs regularly at VASCA meetings.



Source: Jakub Sliva

What is one thing that you would like the general public to know about the reality of living with a rare disease (or caring for someone with a rare disease)?

The majority of the general public in Czech Republic has no awareness and information about rare diseases in general or find the issue too distant and alien, but almost everyone has someone in their immediate or distant environment who is living or has lived with a rare disease. The role of ERNs, national alliances on rare diseases and patient organisations is therefore very important, not only to spread awareness of individual rare diseases, but also to provide or ensure prompt and effective treatment for all of us "rare" people.

As a patient advocate, what is your hope for VASCERN and for the ERNs in general?

Despite all the difficulties and crises that our world has experienced in recent years, I firmly hope that the functioning of these large patient projects and their goals will not be compromised in any way and that they will provide more and more support and help to both doctors and patients with rare diseases in the future. I would like to see Europe's political and economic interests increasingly aligned with those of patients, so that the European Reference Networks are stable and sustainable in the long term.



Carminda Alves Gonçalves answers questions about her work, her personal motivations, wishes and hopes for the ‘ERN’ project

Carminda Alves Gonçalves (andLINFA)



Source: Filipe Gonçalves

Can you tell us something about the reasons for your commitment?

I am the mother of a boy born in 2010. When I found out about the disease which had affected him since birth, we went to a hospital in the USA where we finally received confirmation of the diagnosis in 2012: Klippel Trenaunay syndrome and primary lymphedema of the left lower limb.

Having encountered multiple difficulties on our journey over these years (delayed diagnosis, absence of information on how to care for the condition and what we could do to improve his quality of life) I decided to share with everyone how we overcome these difficulties, and in turn help other families if possible.

How did you become involved in the VASCERN project?

My dedication to spreading awareness of the disease led me to working with andLINFA patient organisation, where I am a board member. The president of this association invited me in 2021 to represent children with Klippel Trenaunay syndrome in VASCERN, in the VASCA working group.

How do you as an ePAG patient advocate participate in the activities of VASCERN?

As I have only recently started participating, I am still learning, and I hope to be able to contribute more actively in the near future.

What is one thing that you would like the general public to know about the reality of living with a rare disease (or caring for someone with a rare disease)?

People may view patients living with a rare disease as somehow different but it is often only the appearance that sets them apart. Everyone must realise that we are unique, but equal.

As a patient advocate, what is your hope for VASCERN and for the ERNs in general?

I hope my collaboration will be useful so that everyone can have quick access to diagnosis and correct information about their treatment. And that this information would be accessible and equal in all countries.



Group photo of VASCERN ePAG advocates at their Spring Meeting in Paris, June 2023

Source: VASCERN

VASCERN: Achievements in the First 5 Years

Prof. Guillaume Jondeau, Julie Hallac, Natasha Barr, Yaël Glin, Ibrahim Donmez, Treasure Udechukwu, Gloria Somalo Barranco

VASCERN, the European Reference Network on Rare Multisystemic Vascular Diseases, is one of the 24 European Reference Networks for rare, low-prevalence and complex diseases. February 28th, 2022 marked the end of the first five years of the ERNs and therefore it is the perfect time to look back at what has been accomplished by VASCERN in the first 5 years.

VASCERN's main aims have been to define what is considered optimal care for the rare vascular diseases covered by the network and to facilitate access to that optimal care for all patients in Europe.

This has been done by working towards the targets of the 15 work packages set out by VASCERN, which have been achieved thanks to the expertise of our members and the fluid collaboration witnessed in all of the RDWGs (Rare Disease Working Group), facilitated by regular online and face-to-face meetings organised by the VASCERN coordination team.

Tools to Improve the Care and Diagnosis

Clinical decision-making tools produced (and in many cases translated) by VASCERN include Do's and Don'ts factsheets (23 new factsheets produced since last year, total of 87 available); patient pathways (renamed diagnostic and management pathways, currently available for eight diseases/groups of diseases); and consensus statements.

Clinical outcome measures, which aim to evaluate the quality of care provided to patients, are another work package that VASCERN has been advancing on, with the HHT WG already having published five outcome measures and the other RDWGs currently defining theirs.

Research

VASCERN has made collaborative research more attainable and we have had numerous collaborative research projects ongoing in the past five years involving our members, with over 45 collaborative publications appearing in peer reviewed scientific journals. Due to the rarity of many of VASCERN's diseases and the consequent lack of robust data, Clinical Practice Guidelines (CPGs) have not yet been produced by VASCERN, however many international or European CPGs have been identified and adopted by our RDWGs, many of which are co-authored by our members.

The VASCERN Registry Project is in full swing and will be fundamental for the collection of the precious patient data needed to reinforce research and epidemiological surveillance. The six working groups are all at different stages in the development of their registries, with some ready to start collecting patient data.

eHealth Activities

In terms of educational material we have developed an extensive collection of Pills of Knowledge (PoK) videos, which thanks to our members have subtitles available in various EU languages.

We have equally hosted 12 live webinars. The VASCERN YouTube channel currently has 12 playlists and over 130 videos, including PoK videos, webinar recordings, instructional tutorials, promotional videos and congress or meeting recordings. The PoKs and webinars will be gathered and added to the future European Commission's Moodle e-learning platform, along with the interactive e-learning modules which are currently being developed.

We have also been active in providing expert advice via the Clinical Patient Management System (CPMS), with over 147 panels opened during the past five years.

The VASCERN App, a tool created to facilitate cross-border healthcare by allowing patients to find the closest expert center or patient organisation near them, currently includes datasets from 47 expert centers who are full members, 6 affiliated partners, 55 referral centers and 73 patient organisations.

Lastly, our communication activities have also continued to grow in the past five years, allowing VASCERN and the outputs mentioned above to reach progressively more people.

This is evident in the increased page views on our website, increased followers on our four social media channels and the almost 1000 subscribers of our monthly newsletter, as well as notable partnerships with national/international scientific



VASCERN Days in Paris, October 2022: group picture

Source: VASCERN

societies and patient organisations. The members of VASCERN participate actively in raising awareness for our network by speaking about VASCERN at conferences and meetings all over the world.

To increase the accessibility of our outputs we continue to translate our videos and documents as much as possible. All translated material can be found on the “VASCERN Resources in all EU languages” page of the VASCERN website.

A Fruitful Partnership

After seven years, we can proudly say that VASCERN has achieved many things but the most notable is the strong collaboration between all of our recognised international experts and our active patient advocates who are passionately working together in order to improve the lives of rare vascular disease patients in Europe.

While there is still much work to be done, VASCERN is now ready for this next chapter and looks forward to the coming five years and what they will bring.



For more information about VASCERN’s activities, please read *The VASCERN European Reference Network: An Overview*, published in the *European Journal of Medical Genetics* or visit our website.

- <https://vascern.eu>
- www.sciencedirect.com/science/article/pii/S1769721222000015?via%3Dihub

▼ Please scan ▼



Latest Changes in VASCERN

Prof. Guillaume Jondeau, Julie Hallac, Natasha Barr, Yaël Glin, Ibrahim Donmez, Treasure Udechukwu, Gloria Somalo Barranco

VASCERN has seen significant growth and evolution over the past year and a half, including:

- **13 New Healthcare Provider (HCP) full members**

The evaluation process of the applicants for the 2019 call for membership to the existing European Reference Networks (ERNs), which had been ongoing for two years (due to COVID-19 delays), finally came to an end with the official approval of 13 new Healthcare Provider (HCP) members joining VASCERN on January 1st, 2022.

With these new members VASCERN now gathers 48 expert teams from 39 highly specialised multidisciplinary HCPs plus six affiliated partner centres, coming from 19 EU Member States.

HCP name	Country	HHT	HTAD	MSA	NEUROV ASC	PPL	VASCA
Aarhus Universitets Hospital	Denmark		✓	✓			✓
Rigshospitalet, Copenhagen	Denmark					✓	✓
Alfried Krupp Krankenhaus, Essen	Germany				✓		
Universitätsklinikum Gießen und Marburg	Germany	✓					
Assistance Publique des Hôpitaux de Paris, APHP nord, Hôpital Lariboisière	France				✓		✓
Fondazione IRCCS Istituto Neurologico Carlo Besta di Milano	Italy				✓		
Vilniaus universiteto ligoninės Santariskiu klinikos	Lithuania						✓
Leiden University Medical Center	Netherlands				✓		
Oslo universitetssykehus	Norway		✓	✓			✓
Centro Hospitalar de São João, EPE	Portugal						✓
Hospital Sant Joan De Déu (SJD Barcelona Children's Hospital)	Spain						✓
Hospital Universitari Vall d'Hebron	Spain		✓				
Akademiska sjukhuset - Uppsala University Hospital	Sweden			✓			

Source: VASCERN

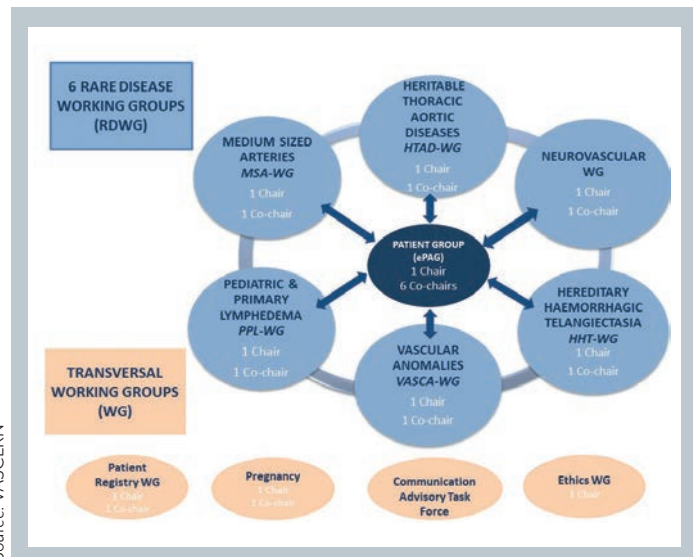
- **New patient advocates join the VASCERN working groups**

VASCERN's ePAG is also stronger than ever with new patient advocates having joined this year for many of our RDWGs. We now have 38 active patient advocates as well as over 73 patient organisations in our ePAG, ensuring that the patient voice is represented in all of our work and for as many of the diseases we cover as possible. The goal is to continue to reach out to patient organisations from countries not yet represented as it is essential for the network to have a large panel of representatives from all across Europe.

- **Creation of a 6th Rare Disease Working Group**

The creation of a sixth RDWG, the **Neurovascular diseases or NEUROVASC working group**, was also solidified as of January 2022 with the arrival of HCPs (Health Care Providers) meeting the specific criteria to be considered

expert centres in CADASIL and Moyamoya, the two diseases currently covered by this group. Four ePAGs have also joined this working group. We are happy that we have been able to expand the disease scope of our network and we will continue to try and fill gaps as they are identified.



Source: VASCERN

- **New members of VASCERN's coordination team**

Marine Hurard, VASCERN's former project manager left VASCERN at the start of 2021 and was replaced by Julie Hallac who took over this key position in May 2021. Project officer Karen Douad also left the team in the summer of 2021 and this position was soon filled by Yaël Glin. Natasha Barr (Scientific and Communications Project Officer) left the team at the end of March 2022 and has since been replaced by Treasure Udechukwu, the new Communication Project Officer in May. A great step towards a greater and more comprehensive support of our RDWG was the creation of a scientific position and the hiring of Gloria Somalo, who joined the team as Scientific Project Officer in October. Ibrahim Donmez (IT Helpdesk & End User Support Specialist) and Pim Kamerling (Data Steward) are still members of the team.

- **New internal communication tool**

Since 2022, VASCERN has implemented its new internal communication tool, Microsoft Teams. This platform gathers all the VASCERN stakeholders and will enable an enhanced flow of information among its members and with the coordination team. Common work on documents will now be technically possible as well as direct chats between members. The coordination team is in the process of training all the clinicians and patient representatives to its use which should enable even more fruitful collaborations in the future.

News from the VASCA WG

Julie Hallac, Natasha Barr, Yaël Glin, Ibrahim Donmez, Treasure Udechukwu, Gloria Somalo Barranco, Prof. Guillaume Jondeau

The Vascular Anomalies Working Group (VASCA WG), one of the now six rare disease working groups of VASCERN, focuses on vascular anomalies. They have grown in the past year with the arrival of 6 new health care provider (HCP) full members from Denmark, France, Lithuania, Norway, Portugal and Spain, as well as two new patient advocates from the Czech Republic and Portugal. They have also been very productive this year with many new projects delivered or underway.

eLearning activities

A new activity started by the VASCA WG has been the production of webinars. The VASCA WG has conducted five webinars to date, directed mainly for healthcare professionals but equally attended by patients interested in learning more about the topics discussed. The topics were: classification of vascular anomalies, giving an overview of the classification of these diseases, followed by a series of four webinars which covered the diagnostic and management pathways for severe and/or rare infantile hemangiomas, lymphatic malformations, venous malformations and capillary malformations. The recordings of these webinars can all be found on the VASCERN Youtube channel.

The webinars and Pills of Knowledge (PoK) videos will be added to the upcoming Moodle platform, the “ERN academy”, along with online course modules on vascular anomalies, starting with a module on arteriovenous malformations, which is currently under development.

Clinical decision making tools

The four diagnostic and management pathways already produced are also being adapted into articles that will appear in scientific publications and will give further detail on the process and proper use of these pathways. The first publication, entitled The VASCERN-VASCA working group diagnostic and management pathways for severe and/or rare infantile hemangiomas is already available online in the European Journal of Medical Genetics. Additional pathways are also being developed for arteriovenous malformations, complex vascular anomaly syndromes and a general pathway tying all of the vascular anomalies together.

In addition to the clinical decision making tools already mentioned, the production of Do's and Don'ts factsheets on various vascular anomalies has commenced and the group has also released two documents that were used to help guide vascular anomaly patients during the COVID-19 pandemic: a statement

concerning SARS-CoV-2 vaccination and the general COVID-19 recommendations for vascular anomaly patients, initiated by the patient advocacy groups in Europe and the United States and their medical advisory teams, and approved by the VASCA WG.

Clinical Patient Management System

To ensure cross-border care of rare vascular anomalies patients, the VASCA WG has continued their monthly case discussion meetings using the Clinical Patient Management System (CPMS) and has been one of the most active groups in this activity within VASCERN, producing numerous outcome reports and having had several guest cases discussed from countries not yet in our network.

New projects within the group

The VASCA WG has also created many task forces, focused on a specific project or specialty topic (e.g. anesthesia, radiology), and supported by additional healthcare providers from VASCERN HCPs or, if needed, outside of the network. The ERN exchange programme, funded by the European Commission, allows healthcare professionals from the VASCA WG's expert centers to visit other centers and learn valuable expertise or skills, which should only increase the outputs of the group and give the opportunity for increased networking. The VASCA WG has 12 exchanges completed or planned by January 2024.

The VASCA WG is a dynamic group with a strong team spirit and, with the arrival of the new members, should be able to achieve even more important work in the coming year.



The VASCA WG during the VASCERN days in Paris, October 2022

Introduction of the New VASCA WG Centres



Oslo University Hospital (Norway)

Oslo University Hospital

Rikshospitalet
Sognsvannsveien 20
0027 Oslo
NORWAY



Contact telephone:

+ 47 23 07 42 98

VASCA member:

Dr. Rune Andersen, Radiologist
Dr. Sigurd Berger, Radiologist

www.oslo-universitetssykehus.no/



The vascular anomaly group at the Oslo University Hospital, Norway

Source: Oslo University Hospital, Norway

The multidisciplinary vascular anomaly centre in Oslo University Hospital is located at Rikshospitalet, the main location of Oslo University Hospital. Since about 20 years, the hospital has served as the National treatment centre for vascular malformations and large hemangiomas. This service is formally located at the Department of Plastic and Reconstructive surgery, but several departments are involved making it a complete centre in one single location.

About 500 patients are referred every year, and all patients are evaluated with clinical examination, laboratory studies and imaging studies. In addition to conventional imaging modalities like Ultrasound doppler, CT and MR imaging, we perform intranodal MR-lymphangiography and conventional lymphangiography in patients with complex lymphatic ano-

malies. Treatment options cover conservative and medical treatment, as well as surgery and interventional radiology with embolisation and sclerotherapy.

The centre covers all ages from newborn to adults, and we are lucky to have both adult and paediatric haematologists in our group. A part of the multidisciplinary team meets once a week for short discussions of patients and the entire team meets once a month for discussions of more difficult cases, often with the patient and relatives in the room. In April 2022, we started the inclusion of our patient population in a new quality registry, and this registry will be transformed into a quality- and research registry within 2024. Oslo University Hospital also serves the majority of HHT patients in Norway, and in particular all HHT patients with pulmonary AVMs.



Copenhagen University Hospital (Denmark)

Copenhagen University Hospital

Inge Lehmans vej 6
Section 6033
DK-2100 Copenhagen
DENMARK



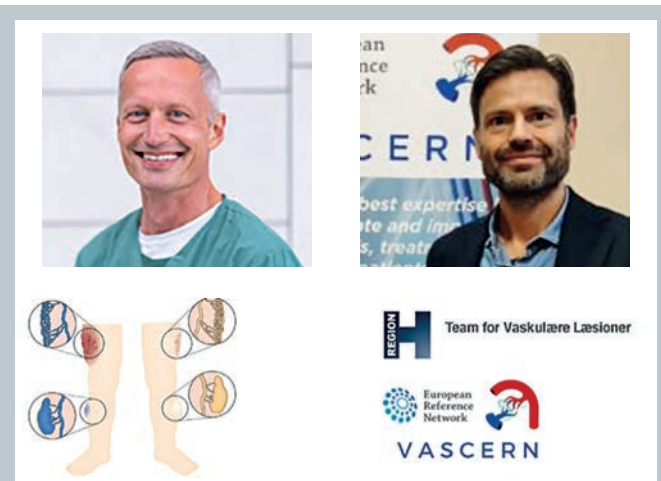
Email:

vascular-team.rigshospitalet@regionh.dk

VASCA member:

Dr. Mikkel KALTOFT, otorhinolaryngologist
Dr. Thomas HJULER, paediatric otorhinolaryngologist

www.rigshospitalet.dk/afdelinger-og-klinikker/tvaergaende_enheder/vaskulaere-laesjoner/om%20teamet/Sider/Organisation.aspx



Thomas Hjuler, Mikkel Kaltoft - VASCA members from the Vascular Anomaly Team, Copenhagen University Hospital

Source: Copenhagen University Hospital Denmark



Hospital Sant Joan de Deu (Spain)

Hospital Sant Joan de Deu

Passeig Sant Joan de Déu, 2,
08950 Esplugues de Llobregat (Barcelona)
SPAIN



VASCA member:

Dr. Eulalia Baselga, paediatric dermatologist
Dr. Miguel Bejarano, paediatric surgeon

www.sjdhospitalbarcelona.org



The Vascular Anomalies Multidisciplinary Team UAMVHE at Hospital Sant Joan de Déu, Spain

Source: Hospital Sant Joan de Deu, Spain

The Vascular Anomalies Multidisciplinary Team (UAMVHE) at Hospital Sant Joan de Déu provides comprehensive care for children with vascular anomalies. Our multidisciplinary clinics operate weekly, bringing together a team of experts including dermatologists, surgeons, interventional radiologists, paediatricians, hemato-oncologists, and, if required, orthopaedic surgeons, otorhinolaryngologists, and ophthalmologists.

As part of our commitment to accurate diagnosis, we routinely conduct genetic analyses, examining mosaic variants in both tissue and blood. From an imaging perspective, our facility is equipped with bedside ultrasonography, a 3-Tesla MRI, expertise in MR-lymphography, and lymphoscintigraphy. Safety is a top priority in our Children's Hospital, reflected in our use of the minimum radiation dose and minimal contrast dose tailored to the patient's age and weight.

Our multidisciplinary approach allows patients to benefit from the latest, integrated, and personalised treatments. Our

services encompass the full spectrum, ranging from medical to surgical interventions, including sclerosis, embolization, cryoablation, electroporation, and laser therapy. Our Laser Unit is equipped with state-of-the-art technology, featuring PDL, Nd-Yag, CO2 lasers, and endovascular lasers, administered under local or general anaesthesia as needed.

In addition to our clinical services, we have a dedicated research unit that investigates the mechanisms involved in the development of vascular anomalies. Through the use of animal models and cultured endothelial cells from patients, we strive to advance our understanding and improve treatment outcomes for our patients

Sant Joan de Deu is a university, third level Hospital and international patients are always welcomed. Our facilities, built for children, ensure the best possible experience for our patients. We have unique and newly renovated neonatal and paediatric intensive care units.

At Copenhagen University Hospital we have had a multidisciplinary team working with vascular anomalies for more than 20 years, and since January 2022 we are member of the VASCA working group within the VASCERN European Reference Network.

The team has members from a wide variety of specialties: dermatology, interventional radiology, medical genetics, odontologic surgery, ophthalmology, orthopaedic surgery, otolaryngology, paediatrics, pathology, plastic surgery and vascular surgery.

All cases from eastern Denmark can be referred to the team as well as complicated cases from all of Denmark. The patients are referred to the clinical departments, primarily plastic surgery, otolaryngology, paediatrics and vascular surgery, and the initial examination is performed here. When we have more

complex patients who need treatment involving more than one specialty, we have the possibility to discuss the patients at our multidisciplinary team meetings, where specialists from all the involved specialties attend. The meetings are held on a monthly basis. Approx. 300-400 new patients are referred to our team each year, and we discuss around 150 of them at our multidisciplinary team meetings.

We treat both children and adults at our centre. We have several treatment options available: Surgery, sclerotherapy, embolization, laser treatment and compression. In recent years, medical treatment (mainly with Sirolimus) has been used in an increasing number of cases.

Working together with the VASCA working group enables us to ensure even better standards of treatment and to get help with difficult cases.



Centro Hospitalar Universitário São João (Portugal)

Centro Hospitalar Universitário São João (CHUSJ)

Alameda Professor Hernâni Monteiro
4200-319 Porto
PORTUGAL



VASCA member:

Dr. Maria do Bom-Sucesso, paediatric oncologist
Dr. Miguel Madureira, interventional radiology

<https://portal-chsj.min-saude.pt/>



ANOVASC Multidisciplinary team at the Centro Hospitalar Universitário São João, Portugal

Source: Centro Hospitalar Universitário São João, Portugal

CHUSJ is a type III level University Hospital with all adult and paediatric specialities, subspecialities and resources. The CHUSJ Multidisciplinary Vascular Anomalies Group - the ANOVASC Group - encompasses paediatric and adult specialities, including paediatric oncology, dermatology, interventional radiology, pathology, paediatric surgery, plastic surgery, clinical genetics, internal medicine, ENT, ophthalmology and orthopaedics. It has a core and an extended team with weekly multidisciplinary team consultations and is coordinated by Dr. Maria do Bom-Sucesso, paediatric oncologist. Beyond interdisciplinary approach, patients have access to several specialised resources like ultrasound evaluation with doppler assessment, MRI with anaesthesia, CT, intranodal lymphangiography, lymphoscintigraphy, angiography with 3D reconstructions, sclerotherapy, embolisation, radiofrequency ablation, percutaneous biopsy, operating theatres, digital dermoscopy, laser, tissue and tumour biobank and medical therapy, including off-label medications.

This ensures access to the latest treatments approved by the EMA and national medication agencies. Genetic tissue analysis, performed in cooperation with IPATIMUP (Institute of Pathology and Molecular Immunology of the University of Porto) enables the possibility of target therapy and precision medicine in vascular anomalies. Recognizing the complexity of chronic diseases, the ANOVASC group integrates a palliative care philosophy from the moment of diagnosis. Our patient and family-centred approach encompasses psychological, social, educational, and rehabilitative support. The multidisciplinary team is actively engaged not only in post-graduate but also in pre-graduate education, through the Medical Faculty of Porto University. The ANOVASC group also organises the National Congress of Vascular Anomalies every two years, since 2016. In 2022, HCP CHUSJ joined ERN VASCERN-VASCA through its representative Dr. Maria do Bom-Sucesso, paediatric oncology and sub-representative Dr. Miguel Madureira, interventional radiology.



Vilnius University Hospital Santaros Klinikos (Lithuania)

Vilnius University Hospital Santaros Klinikos

Centre of Congenital Vascular Anomalies
Santariskiu st. 2
08661 Vilnius
LITHUANIA



VASCA member:

Dr. Biruté Vaišnytė, vascular surgeon
Dr. Darius Palionis, radiologist

www.santa.lt/about-center-cva/



The Centre of Congenital Vascular Anomalies's team at Vilnius University Hospital Santaros Klinikos, Lithuania

Source: Vilnius University Hospital Santaros Klinikos, Lithuania



Lariboisière Hospital (France)

Lariboisière Hospital

National rare disease centre for superficial vascular anomalies in adults and children (= CNMR AVS de l'enfant et de l'adulte)

Consultation des angiomes /

Anomalies Vasculaires superficielles de l'enfant et adulte

2, rue Ambroise Paré

75010 Paris

FRANCE



Phone:

+330149958359

Email:

○ consultation.angiomes@lrb.aphp.fr

VASCA member:

Dr. Annouk Anne Bisdorff-Bresson, interventional radiologist

Dr. Olivia BOCCARA, dermatologist and venereologist

○ <https://hopital-lariboisiere.aphp.fr/>



The Vascular anomalies team from the Lariboisière Hospital, France

Source: Lariboisière Hospital, France

The multidisciplinary vascular anomalies clinic (=VAC) was set up in 1976 at Lariboisière hospital by Professor JJ Merland and Dr Marie-Claire Riché, both interventional neuroradiologists, and was later on coordinated by Dr Odile Enjolras until 2007. It was the first of its kind in Europe at that time, since then numerous centres in France and Europe were created on the same model.

The clinic and team are made up of multidisciplinary expert clinicians trained at Lariboisière and in international teams. Taking care of children and adults with vascular anomalies in all body locations (cervico-facial, limbs and trunk).

We see about 1300 patients / year in the clinic and perform between 250-300 procedures/year including sclerotherapy, embolization, endovenous laser treatment and excision surgery.

The specialties represented are anatomo-pathology, dermatology, maxillofacial and ENT surgery, vascular surgery, vascular medicine, haematology, genetics and interventional radiology. Local and national multidisciplinary consultation and interdisciplinary national web meetings are held on a regular basis. Since 2023 the centre has been recognized as the coordinating national centre of rare disease in superficial vascular anomalies for France. The French network for superficial vascular anomalies also includes two constituent centres (Lyon and Montpellier) and 12 different competence centres.

This network is included in the Filière FAVA-Multi. The centre participates in clinical and basic science national and international research studies (<https://favamulti.fr/>).

The Centre of Congenital Vascular Anomalies at Vilnius University Hospital Santaros Klinikos was established on June 25, 2012. It is the only place for the diagnosis, treatment, training and research of congenital vascular diseases in Lithuania. Our centre is coordinated by Dr. Birutė Vaišnytė and it currently employs 33 doctors of various specialities. Depending on the localisation and spread of the pathology, patients are thoroughly examined, appropriate specialists are consulted, joint meetings and councils are organised, and patients are often operated with the participation of surgeons of various specialities. The Centre uses the most advanced diagnostic and treatment technologies: dynamic contrast magnetic resonance angiography (DCE-MRA) - for the diagnosis and differential diagnosis of vascular anomalies, post-treatment control; transarterial perfusion pulmonary scintigraphy (TLPS) - for the assessment of arteriovenous drainage in arteriovenous malformations; interventional angiography, computed tomography angiography

(CTA), vascular duplex ultrasound scanning, genetic testing, complex surgical operations for highly spread intravascular arteriovenous malformations, intramuscular malformations, endovascular treatment of congenital vascular abnormalities, combined surgical and endovascular treatment, laser therapy. Sirolimus (rapamycin) therapy is already available for our patients. Psychological and social assistance is also provided for our patients as well. Patients of all ages are treated and monitored throughout their lives in the Centre. There are over 2,000 people in our patient monitoring system and up to 700 patients are consulted per year. The activities of our centre are inseparable from the activities of Vilnius University: research and training are carried out here, including university and postgraduate studies at all levels, improvement courses and other teaching activities, conferences, seminars and congresses are organised. All this guarantees the dissemination, continuity, and continuous progress of knowledge and expertise.

ERN Academy Moodle Platform

Yaël Glin, Julie Hallac, Prof. Guillaume Jondeau

The ERN Academy is a cross-ERN project that the European Commission is setting up for all doctors and patients to know more about rare diseases.

In collaboration with the French national network for rare vascular diseases FAVA-Multi, the VASCA-WG (vascular anomalies working group) and the coordination team are developing VASCERN's first specific module on vascular anomalies and will expand the course in the future with new materials.

The VASCA-WG members develop the content of the course, which is then put into a step-by-step interactive course designed by the coordination team.

After the user completes the course, he/she will be invited to also watch the relevant and existing Pills of Knowledge and/or webinars, which are already available on our website and Youtube Channel. The module should then be concluded by a quiz that will assess the information gathered by the user.

Continuous improvement of the platform

Accordingly, the data gathered will be used to improve the modules if needed and see what areas the students need to improve on. In the future, case studies on diagnostics and follow up of patients should also be offered to our users in order to improve their practice.



Source: VASCERN

VASCERN's Moodle structure

All the six RDWGs (rare disease working groups) of VASCERN will be covered and have their own modules. VASCERN aims to offer modules both for patients and doctors on all its represented rare vascular diseases.

Pilot phase for the ERNs

The Moodle platform should be available in 2024. The European Commission aims to create a comprehensive platform covering all the rare diseases represented by the 24 ERNs.

Make sure to keep an eye on the VASCERN's progress on the Moodle platform by subscribing to our newsletter.



Source: VASCERN

Group photo at the VASCA WG networking event in Brussels, August 2023

CPMS 2.0: A User-Friendly Solution for Cross-Border Clinical Discussions

Prof. Leo Schultze Kool, MD, PhD

The CPMS is a web-based application designed to support European Reference Networks (ERNs) in improving the diagnosis and treatment of rare or low prevalence complex diseases across national borders in Europe. Through this platform, healthcare professionals affiliated to a particular ERN can discuss patient cases. These virtual consultations are available on request to healthcare professionals, whether specialists or not, practising in any EU country.

The aim is for the team of experts in the ERN to provide guidance on a complex case at a critical stage in the patient's journey.

If you would like to submit a case, please contact the VASCERN Coordination Team. Do not hesitate to read the **introductory CPMS article on pages 16-17 of VASCA Magazine Issue 1** (see below).

There is promising news regarding the evolution of the Clinical Patient Management System (CPMS): In recent years, challenges with the existing system, particularly in terms of complexity and compliance with GDPR (General Data Protection Regulation), have become clear. The European Union recognised the need for improvement and took action.

A New Solution for Better Care

The EU has proposed the development of a new consultation software/platform to address these challenges. This innovative IT platform is designed to support seamless cross-border clinical discussions. It will be accessible on both desktop and mobile devices, ensuring convenience for healthcare professionals in all Member States. After a rigorous selection process, IBM was chosen as the collaborator for CPMS 2.0.

A Collaborative Approach

The development of CPMS 2.0 is a collaborative effort involving various stakeholders, including end-users. The methodology includes regular meetings and workshops to gather feedback and insights, ensuring the



Leo J. Schultze Kool, MD, PhD, EBIR

Photo: Leo J. Schultze Kool

platform meets the specific needs of all 24 European Reference Networks.

CPMS 2.0 will be intuitive and straightforward, making it easy for healthcare professionals to navigate and use its features effectively.

To encourage transparency and collaboration, CPMS 2.0 will be based on open-source technology. This approach allows for flexibility and adaptability, ensuring that the platform can be tailored to meet the unique needs of different healthcare networks and Member States.

Safety and Security First

Patient confidentiality remains a top priority. The new platform is not only secure but also fully compliant with GDPR regulations. This means that personal information will be handled with the utmost care and in accordance with the highest privacy standards. The development plan is well underway, with an imminent release of the minimal viable workable system (MVP). The first release will be for the desktop, followed by a mobile version in 2024 to further optimise the system.

With these advancements, CPMS 2.0 will be the next generation in cross-border clinical consultation. This powerful platform represents a significant step forward in ensuring that patients receive the best possible care, regardless of geographical boundaries.

Prof. Leo Schultze Kool, MD, PhD
 Interventional Radiologist
 Radboud University Medical Center
 ● leo.schultzekool@radboudumc.nl
 ● www.radboudumc.nl

Please scan

<p>Website</p> 	<p>Issue 1</p> 
---	--

EURORDIS' Role in Fostering Patient-Clinician Partnership in the European Reference Networks

Ines Hernando

EURORDIS-Rare Diseases (*1) Europe is a unique, non-profit alliance of 1000 rare disease (RD) patient organisations from 74 countries that work together to improve the lives of the 30 million people living with a rare disease in Europe.

By connecting patients, families, and patient groups, as well as by bringing together all stakeholders and mobilising the rare disease community, EURORDIS strengthens the patient voice and contributes to shaping research, policies, and patient services.

We advocate at the European and international levels to make rare diseases a public health priority and have created numerous initiatives to make the voice of patients affected by rare diseases heard by policy makers, researchers and society, including the Network of Parliamentary Advocates for Rare Diseases made up of European and national Members of Parliament, Rare Disease Day, the EURORDIS Open Academy and the NGO Committee for Rare Diseases at the UN, to name just a few.

EURORDIS also dedicates substantial efforts to empower and train people living with a rare disease and to build partnerships with other stakeholders involved in health care, diagnosis, therapeutic development, and research.

In the area of health care, for years, EURORDIS has led the rare disease patient community's advocacy efforts to create the European Reference Networks (ERNs) [1] (*2) and worked hand in hand with all stakeholders to develop the policy recommendations that helped to shape the structure and scope of the Networks.

The ERNs have given clinicians and patient organisations the opportunity to co-build better health care services for persons with rare diseases and accelerate research on an unprecedented scale – both in terms of its scope and breadth.



Patient-clinician partnership at a European level to transform healthcare services and define standards of care is relatively new compared to other areas, such as medicines development where there is a long tradition of RD patient involvement and where the role of patient representatives is recognised and well-established [2].

Since the launch of the Networks, EURORDIS has worked to ensure that patients are integrated into the governance and strategic and operational delivery of the ERNs through the creation of 24 European Patient Advocacy Groups (ePAGs), which bring together over 300 patient advocates who are actively involved in the ERNs. ePAG advocates play a fundamental role to connect the Networks with the wider rare disease patient community and, where relevant, to champion the diversity of views of the wider patient community relevant for each ERN, and not just of their own disease area.

ePAG advocates partner and collaborate with the clinicians from “within the ERNs”, rather than influence and advocate from outside the Networks.

For this collaboration to work, each ERN must put in place a robust and inclusive governance to allow meaningful exchanges and shared leadership. However, just as important is the recognition and mutual respect of the knowledge and expertise that each party brings to the table: clinicians as experts on a given disease and ePAG advocates as the voice of the community of people who are experts on living with these diseases. Understanding how this collective experiential knowledge complements the experts' scientific knowledge to build better health care for rare diseases is key to building a healthy collaboration, trust and partnership in the ERNs.

To fully understand the role of ePAG advocates in the ERNs, it is useful to refer to the Patient Partnership Framework developed by the Canadian Centre of Excellence on Partnership with Patients & the Public (*3) that differentiates between 3 levels of engagement, each requiring different skills and knowledge, summarised in figure 1.

Source: Centre of Excellence on Partnership with Patients and the Public, framework presented at the EURORDIS all-ePAG meeting, Vienna 2018.

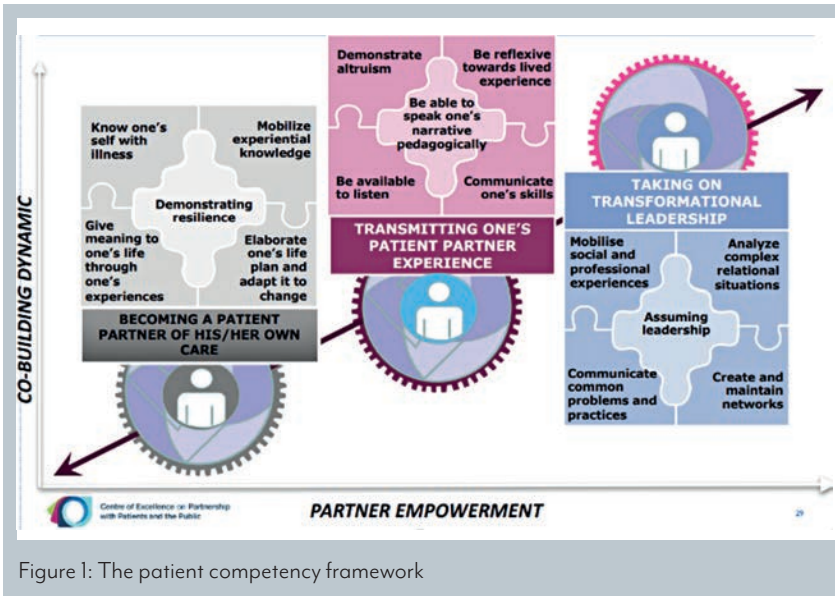


Figure 1: The patient competency framework

The central task of EURORDIS patient engagement managers is to support and provide patient representatives with the knowledge and skills they need to engage and partner effectively with clinicians in ERN activities. They undertake this by leading topic-based working groups, facilitating peer-to-peer learning (*4) and developing “how to” guides on patient engagement. The peer learning sessions and guides, as well as some team-building activities, are also targeted at ERN clinicians and project managers, as members of the same team.

A lot has been achieved over the last five years, but the patient-clinician partnership still needs to be nourished and further developed. In the next stage of the Networks’ development, EURORDIS is committed to continuing to work with ePAG


Depending on how they contribute to a given ERN collaborative activity, ePAG advocates can either fall under the second level, the third level or a mix of both. For example, in the development of a consensus statement, ePAG advocates may simply be asked to share their own experience with the disease (second level), or they might also be asked to share more broadly the perspective of their patient community (third level). This is often the case. Taking a transformational leadership role is what is expected from the patient representatives working in the ERN, and this is not an easy task.

leads, ERN clinicians and project managers to strengthen patient partnerships and build quality collaborative practices.

To ace as a team, ePAG advocates and clinicians must develop and maintain a set of soft skills that they acquire over time and at a different pace.

These include soft skills such as teamwork, communication, conflict prevention and resolution, and collaborative leadership[3].

In addition, ePAG advocates must also develop a good level of understanding of a wide range of topics, such as clinical decision support tools, including methodological aspects, principles of social research, health data, research and registries, patient outcome measures, health services, quality assurance etc. Finally, having a clear and shared understanding of each other’s roles and responsibilities is a fundamental basis for a well-functioning patient-clinician partnership in the ERNs.



Source: Inés Hernando

References

[1] G. Jondeau, M. Hurard, N. Barr, K. Daoud, and I. Donmex, “The European Reference Networks,” VASCA Magazine, p. 11, Apr-2021.

[2] Y. Le Cam and M. Bolz-Johnson, “Expert by Experience: Valuing Patient Engagement in Healthcare,” 2019, pp. 233–267.

[3] Université de Montréal, “Competency Framework for Collaborative Practice and Patient Partnership in Health and Social Services.” Montreal, Québec, 2019.

TEXTLINKS:

(*1)



(*2)



(*3)



(*4)



Ines Hernando
 ERN and Healthcare Director, EURORDIS
 Master in Health Economics, Policy and Management from the London School of Economics

✉ ines.hernando@eurordis.org
 🌐 www.eurordis.org

▼ Please scan ▼

Website

Progression of Vascular Malformations, Factors of Influence

Carine JM van der Vleuten, MD, PhD

Introduction:

Vascular malformations are often said to remain stable during life and grow proportionately with the child, unlike infantile haemangiomas in which progression (and regression) is a very typical characteristic: not or hardly present at birth, with disproportionate growth in the first four months, followed by slow regression in the following years. (1)

From our clinical practice however, we know that vascular malformations can also be progressive over the course of life, becoming larger and thicker, with increasing symptoms. Certainly, if you compare childhood photos of people with the *status praesens* (initial observation of the patient), it is sometimes surprising how progress has occurred unnoticeably. Some patients with port-wine stains notice increased swellings in the port-wine stain over the course of life, and patients with other vascular malformations also notice a progression of swelling and (pain) symptoms. From arteriovenous vascular malformations, we know that there may be serious progression with increasing deformity, pain and bleeding. Progression is more often experienced during hormonal changes, such as puberty and pregnancy.

So, despite a less progressive course in comparison with infantile haemangiomas, many vascular anomaly patients certainly experience the progression of their condition.

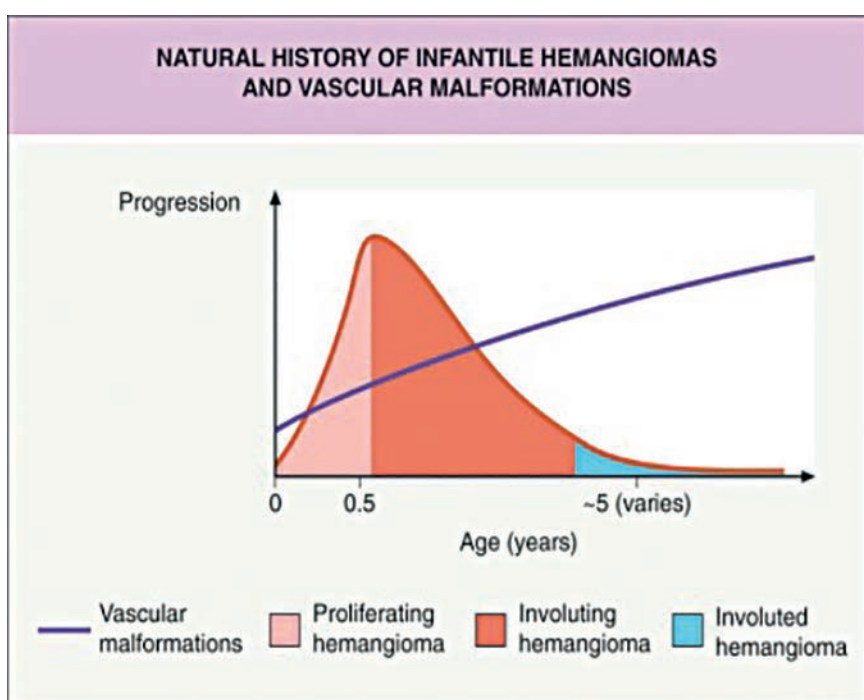
Progression?

The topic of progression of vascular malformations has been investigated in the literature and it has been found that venous vascular malformations (VM) do indeed become larger and more symptomatic over time. (2) In a study of 614 patients, children were found to have a risk of VM progression of 26.1% before adolescence, 74.9% before adulthood, and 93.2% throughout life. (2) It was clear in this study that more progression was to be expected in puberty (60.9%) than in childhood (22.5%) with no differences between male and female. There was no apparent progression of the VM in pregnant women. Diffuse VM showed more progression than localised VM, and VM on the arm, leg or trunk worsened more often than VM in the head and neck area. Comparable progressive courses have been described for other vascular anomalies. (3-5)

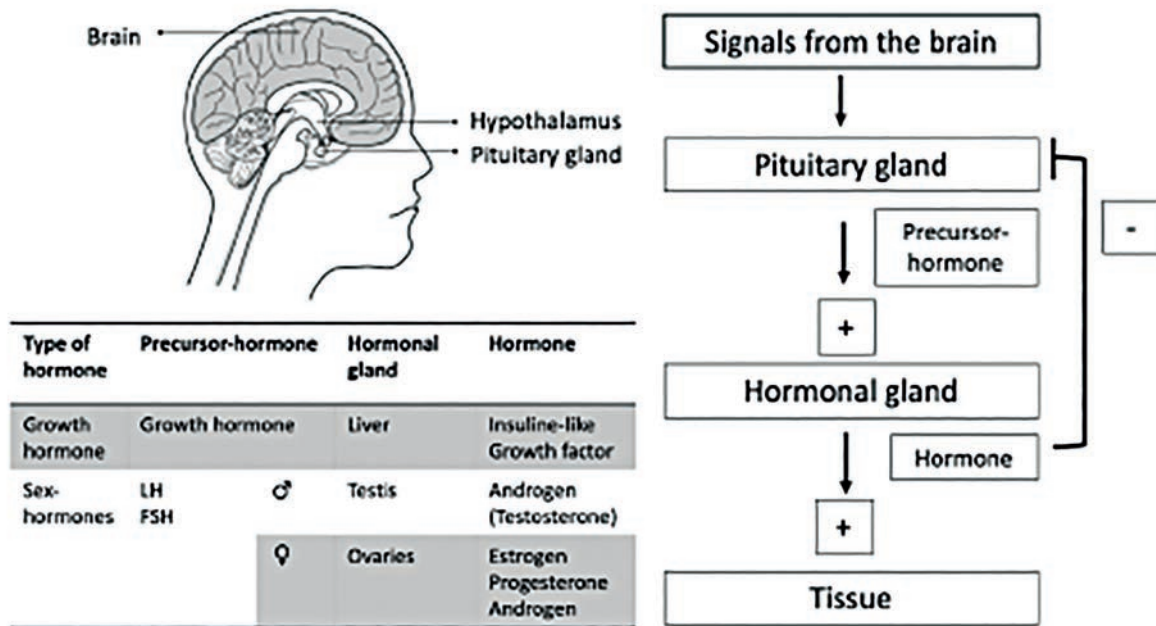
Causes of progression

The question is what is causing this progression. The changes during puberty and pregnancy suggest a **hormonal** component. **Venous congestion** can cause venous hypertension in the limbs or through hemodynamic processes in a port-wine stain resulting in the progression of the lesion during time. Furthermore, superficial or deep vein **thrombosis**, a known complication in low-flow vascular malformations, can cause temporary or permanent progression of symptoms. Another reason for progression is that the tissue of the vascular malformations has different growth properties than unaffected tissue because of the **DNA changes**. Apparently, a different program is being run in the cells of the vascular malformation, often with more growth and activation of the cells.

Source: <https://clinicalgate.com/infantile-hemangiomas-and-vascular-malformations/>



Source drawing (brain/hypothalamus/pituitary gland): https://pnggub.com/png/5AiyY8sPSZ/pituitary-gland-hypothalamus-endocrine-posterior-heart-adrenal-transparent-png



Hormones?

The balance of different hormones is regulated in the brain with various precursor hormones that activate or inhibit hormone-producing glands in the body.

A central role is played by the pituitary gland, which produces precursor-hormones and controls many functions in the body, such as growth, blood pressure, thyroid function and sexual organs. Hormones act on the cell (for example by activating the cell, inciting it to grow) via receptors that make a cell sensitive to certain hormones.

The hormone can do its job if the cell has the right receptor. The question is whether vascular malformations also have receptors for hormones and for which hormones.

Which (precursor) hormones play a role and when?

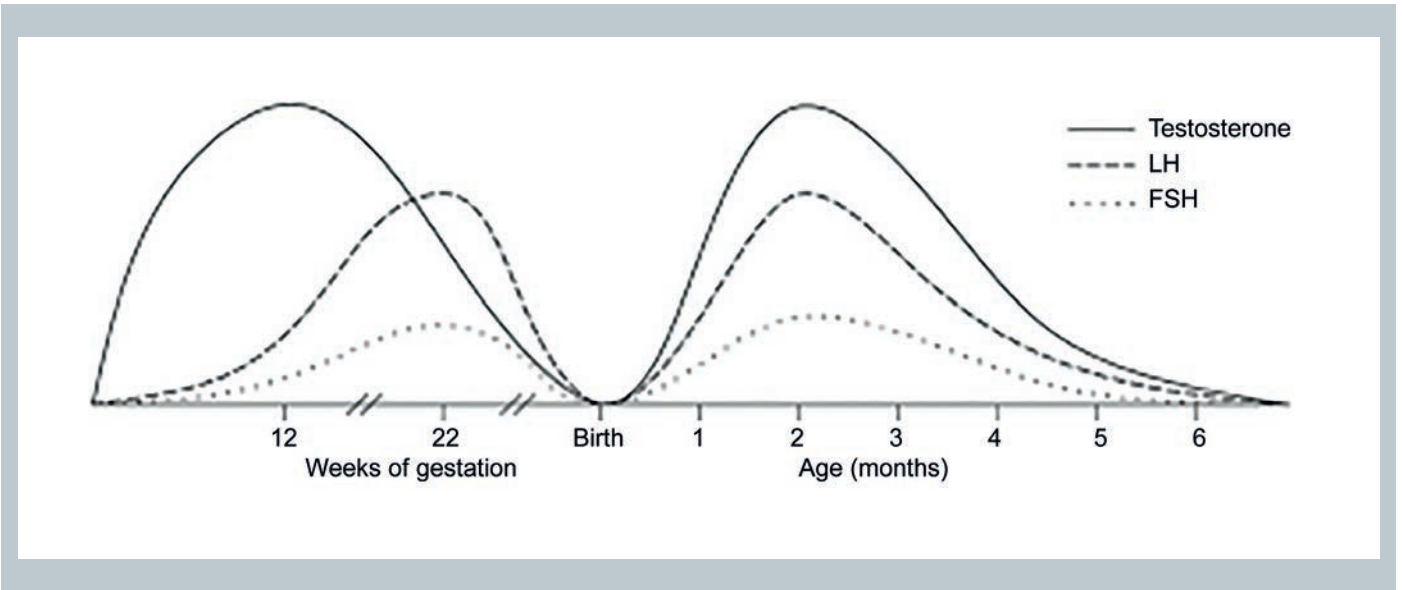
In the study of Kulungowski et al. growth hormone appears to be responsible for progression of the vascular malformation. (6)

Growth hormone peaks in particular during the growth spurt of a child/ adolescent, corresponding to experienced progression of the vascular malformation in that phase of life. Another study (Ventéjou et al.) focused on sex hormones (androgen, oestrogen, progesterone) and identified how triggering factors that aggravate vascular malformations (trauma, infection and hormonal changes) interact with hormones via hormonal receptors in the tissue of the vascular malformation. (7)

In this study of 51 patients with lymphatic, venous, arteriovenous or combined vascular malformations, the expression of sex-hormonal receptors in tissue samples was examined, and the patients themselves were asked to identify triggers that led to exacerbation. It turned out that there were no oestrogen- and progesterone-receptors in the tissue, but there were androgen receptors in 74.5% of the patients; this seemed related to a progression in men and women.

With regard to the sex hormones, one of the precursor hormones (FSH) also appears to play an important role in vascular malformations. The 2014 study by Maclellan et al. looked at infantile haemangiomas as well as vascular malformations. (8) It turns out that FSH actually very well reflects the life cycle of an infantile hemangioma. But FSH also increases during adolescence, when vascular malformations often increase. And in women, FSH levels are also known to fluctuate during the menstrual cycle, explaining the monthly fluctuations during the cycle. The study showed that an FSH-receptor could be located in vascular anomalies.

Source: Lanciotti L et al. Front Endocrinol (Lousanne). 2018 Jul 23;9:410. (9)

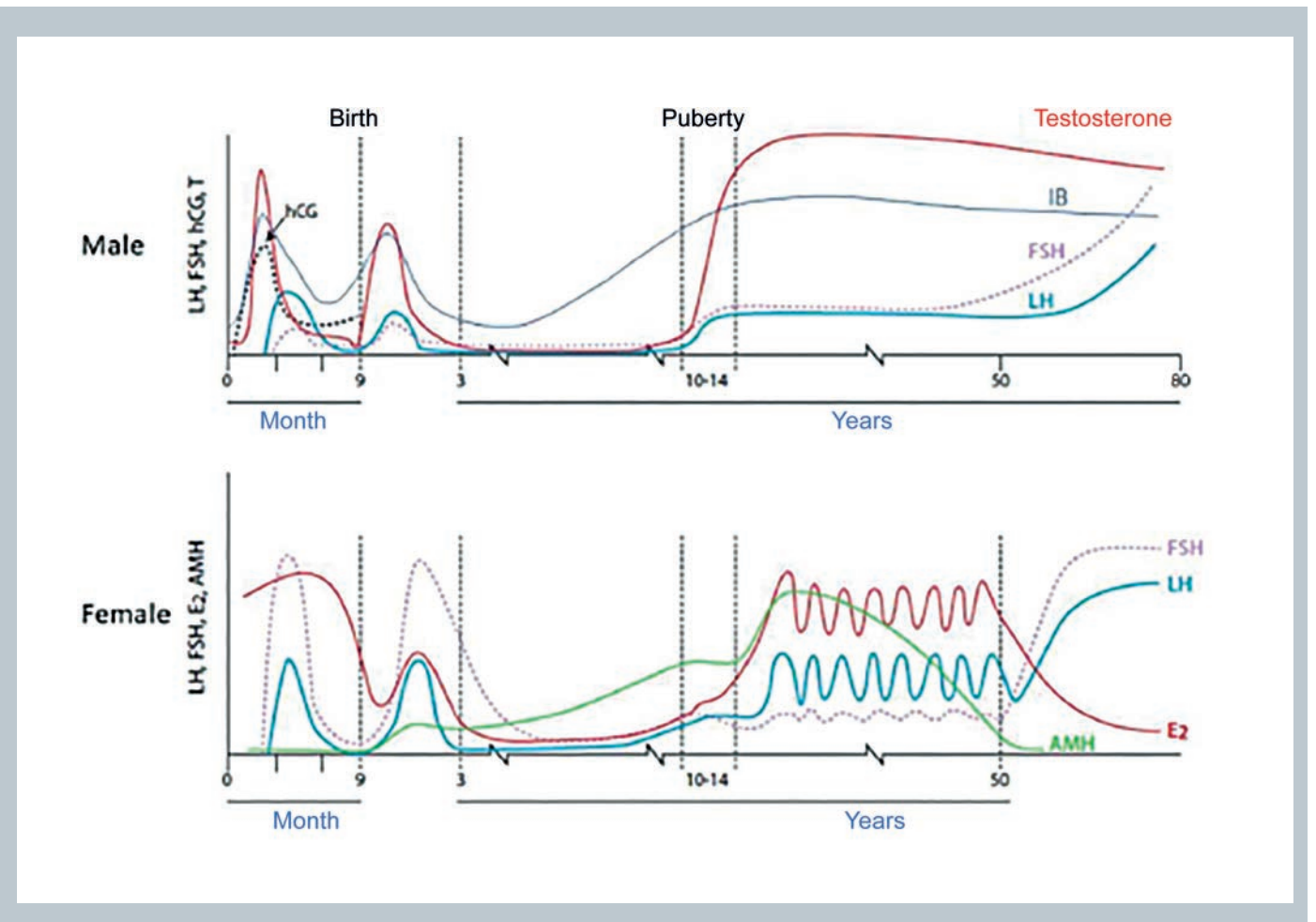


So, in addition to growth hormone, the precursor hormones FSH and androgens seem to play a role and explain progression of the vascular malformation during puberty (men and women) and during the menstrual cycle in women.

Pregnancy

Studies on pregnancy in women with Klippel-Trenaunay syndrome and other vascular malformations are unfortunately relatively scarce. Horbach et al. found that women with complex vascular malformations (Klippel-Trenaunay Syndrome) have an increased risk of thrombosis, major postpartum

Source: Howard SR. Interpretation of reproductive hormones before, during and after the pubertal transition-identifying health and disordered puberty. Clin Endocrinol (Oxf). 2021 Nov;95(5):702-715. (10)



bleeding and worsening vascular malformation. (11) A survey by Blei et al.(12) of 137 women, of which 99 had been pregnant, showed very variable numbers with regards to the use of the birth control pill, rates of miscarriage, caesarean sections and the use of anticoagulants.

From practice, we know there is a variable progression of symptoms. Progression of arteriovenous malformations is often described. Some patients particularly notice progression due to phlebological causes (venous congestion), thrombosis or lymphoedema. But there are also pregnant women who notice little change during pregnancy. It is unclear which factors are at play here. Further research will have to map these factors out so that (potential) pregnant women can be guided as well as possible and avoidable problems can be prevented.

Menopause

A more recent study by Maclellan et al.(13) focuses on the progression of vascular malformations during menopause.

It turns out that FSH increases again during menopause. This seems to be an explanation for the worsening of the symptoms of vascular malformation patients.

Venous congestion

Venous congestion gives rise to increased pressure on the veins and can be seen in the general population in people with

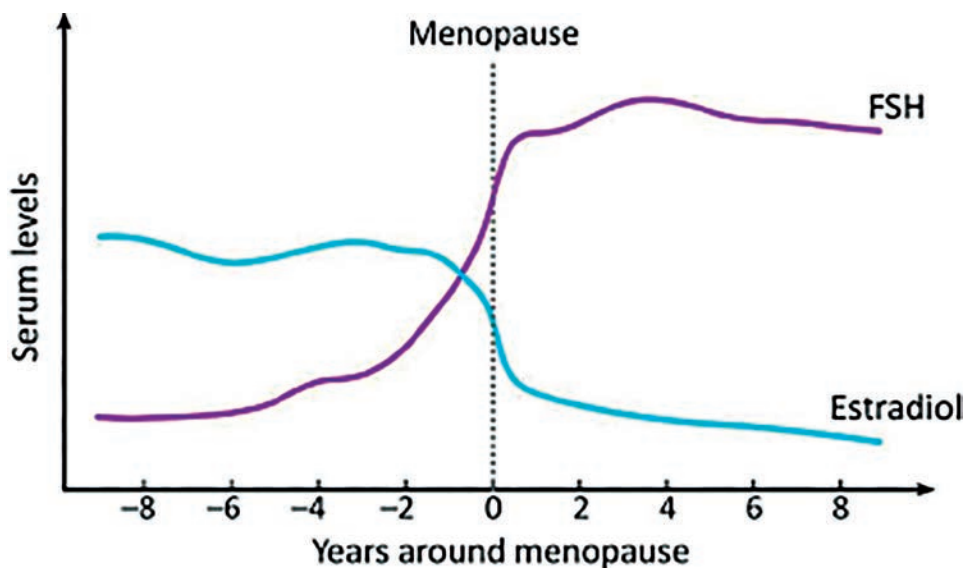
varicose veins. Gravity often plays a role in this. Venous congestion causes symptoms, such as tiredness and heaviness, oedema, pigmentation of the legs and eventually spontaneous wounds that heal poorly (leg ulcer). Typically, these problems increase over time, especially with standing activities or a standing profession.

For some of the (venous) vascular malformations, a similar mechanism plays a role. Depending on the location of the vascular malformation (more often in the leg), the above complaints may occur. But also in arteriovenous malformation patients, due to the shunt between arteries and veins, an increased congestion of veins can occur, resulting in a comparable progression of symptoms.(15)

Thrombosis

Thrombosis is the occurrence of blood clots inside veins, which can cause pain and swelling of the affected part of the body.

It is known that the risk of thrombosis is increased in low-flow vascular malformations and that thrombosis can already occur at a relatively young age. (16, 17) In addition to the fact that thrombosis can cause acute and chronic pain and swelling symptoms in this group, it can also lead to further progression of the vascular malformation itself: pain, increased swelling, consumptive coagulopathy (and pulmonary embolism in Klippel-Trenaunay syndrome). For this reason, anticoagulation is increasingly being chosen, even in people who have 'only' experienced superficial venous thrombosis,



Trends in Endocrinology & Metabolism

Source: Zhu D et al. Extragonadal Effects of Follicle-Stimulating Hormone on Osteoporosis and Cardiovascular Disease in Women during Menopausal Transition. Trends Endocrinol Metab. 2018 Aug;29(8):571-580. (14)

with the aim of reducing chronic pain and preventing more serious manifestations of thrombosis (such as deep vein thrombosis and pulmonary embolism). (16)

Aberrant genetic predisposition

It is now known that in a part of the vascular malformations, a change in the DNA (mutation) is the cause of the condition.

It turns out that in the majority of vascular anomaly patients, such a mutation is only present in the affected tissue (for example, only in the port-wine stain) and the unaffected tissue has normal DNA. These types of DNA abnormalities are called mosaicism and are in principle not hereditary.

The DNA abnormality occurs during the early embryonic phase (between 5-8 weeks of gestation) and the cause is unknown. The mutation in vascular malformations generally

causes the cell to be programmed differently: more active than normal, making more blood vessels or more connective tissue. For example, people with a port-wine stain (more blood vessels) can also get an increase in swelling (more connective tissue growth) in the same localisation at a later age. (5)

Various mutations have now been described to, depending on the tissue where they occur, change the tissue and can also cause increasing symptoms during life and thus progression of the vascular malformation. (18)

And what does this information bring us?

With more insight into factors that cause progression, an attempt can be made to prevent this progression where possible. Understandably, growth and puberty cannot be inhibited in young people, but there are calls to start treating vascular malformations in children before puberty. (2, 4) On the other hand, in daily practice, there is still a reluctance to treat complaint-free children invasively, without knowing exactly what the symptoms will become in the future.

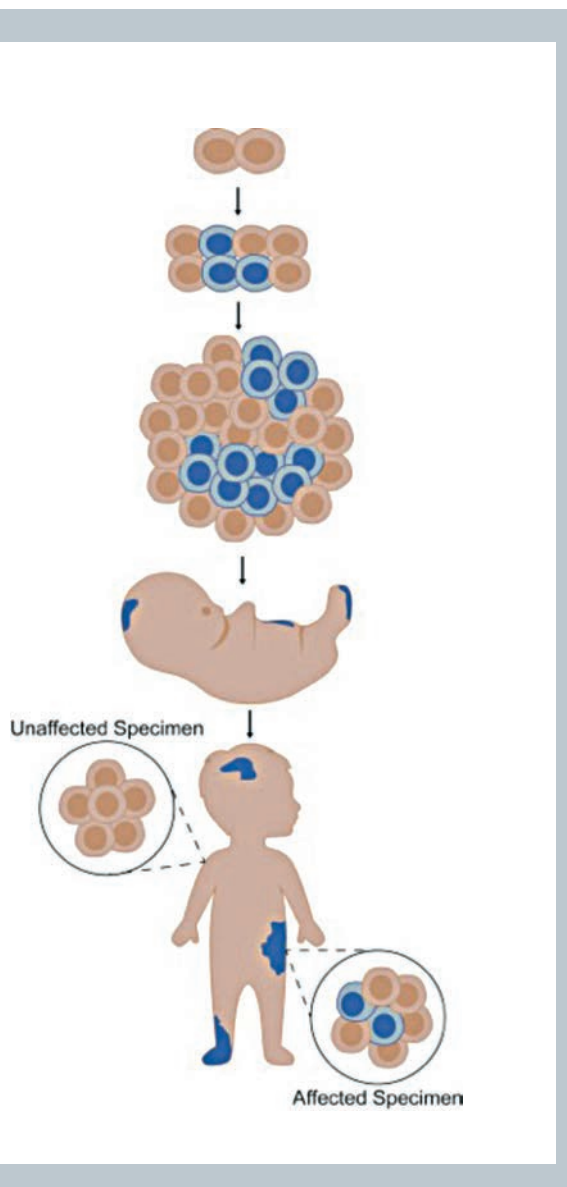
Treatment at a young age has a major impact and is sometimes found difficult to justify.

With respect to menopausal progression, it may be an option to delay menopause as much as possible with hormone supplementation, keeping FSH at premenopausal levels. (13) This kind of advice should also be given with discretion; hormone supplementation certainly has downsides, such as the increased risk of breast cancer.

The risk of thrombosis in low-flow vascular malformations is larger than generally thought. Recognising risk factors (increased d-dimers in combination with chronic pain/ phlebitis) should be a more frequent reason for anticoagulation, especially at times when the thrombosis risk is temporarily increased (pregnancy, immobilisation, perioperatively -i.e. pre, inter and postoperative phases-). (16)

Venous congestion and the progression to more severe manifestations of chronic venous insufficiency can often be addressed with compression stockings and/or varicose vein surgery or interventional radiological treatment.

Finally, the future will show us what exactly targeted therapy, specifically aimed at causal activating mutations, will offer to prevent disease progression and symptoms in our patient population with vascular anomalies, but this approach is expected to offer a new horizon, all with the aim: a life as normal as possible for this group of patients who are regularly very severely affected and limited by their condition. (20)





Carine JM van der Vleuten, MD, PhD

Carine J.M. van der Vleuten, MD, PhD,
dermatologist
Radboud University Medical Center
P.O. Box 9101, 6500 HB Nijmegen (Netherlands)

- Carine.vandervleuten@radboudumc.nl
- www.radboudumc.nl

▼ Please scan ▼

Website



9. Lanciotti L, Cofini M, Leonardi A, Penta L, Esposito S. Up-To-Date Review About Minipuberty and Overview on Hypothalamic-Pituitary-Gonadal Axis Activation in Fetal and Neonatal Life. *Front Endocrinol (Lausanne)*. 2018;9:410.
10. Howard SR. Interpretation of reproductive hormones before, during and after the pubertal transition-Identifying health and disordered puberty. *Clin Endocrinol*. 2021;95(5):702-15.
11. Horbach SE, Lohorst MM, Oduber CE, Middeldorp S, van der Post JA, van der Horst CM. Complications of pregnancy and labour in women with Klippel-Trenaunay syndrome: a nationwide cross-sectional study. *BJOG*. 2017;124(11):1780-8.
12. Blei F FM, Rebarber A Survey Of Females With Klippel-Trenaunay And Similar Vascular Malformations – Focus Of Obstetric And Gynecologic Issues. Poster 101 at ISSVA workshop 2020. 2020.
13. Maclellan RA, Goss JA, Greene AK. Vascular Malformation Enlargement During Menopause. *J Craniofac Surg*. 2018;29(5):1271-2.
14. Zhu D, Li X, Macrae VE, Simoncini T, Fu X. Extragonadal Effects of Follicle-Stimulating Hormone on Osteoporosis and Cardiovascular Disease in Women during Menopausal Transition. *Trends Endocrinol Metab*. 2018;29(8):571-80.
15. Brenner S, Ophir J, Krakowski A, Weinraub Z. Kaposi-Like Arteriovenous Malformation and Angiodermatitis (Pseudo-Kaposi). *Cutis*. 1982;30(2):240-&.
16. van der Vleuten CJM, Zwerink L, Klappe EM, de Jong E, Te Loo D. Is there a place for prophylaxis with DOACs in Klippel-Trenaunay syndrome and other low-flow vascular malformations with intravascular coagulopathy and thromboembolic events? *Thromb Res*. 2022;213:30-3.
17. Domp Martin A, Ballieux F, Thibon P, Lequerrec A, Hermans C, Clapuyt P, et al. Elevated D-dimer level in the differential diagnosis of venous malformations. *Arch Dermatol*. 2009;145(11):1239-44.
18. Ten Broek RW, Eijkelenboom A, van der Vleuten CJM, Kamping EJ, Kets M, Verhoeven BH, et al. Comprehensive molecular and clinicopathological analysis of vascular malformations: A study of 319 cases. *Genes Chromosomes Cancer*. 2019;58(8):541-50.
19. McNulty SN, Evenson MJ, Corliss MM, Love-Gregory LD, Schroeder MC, Cao Y, et al. Diagnostic Utility of Next-Generation Sequencing for Disorders of Somatic Mosaicism: A Five-Year Cumulative Cohort. *Am J Hum Genet*. 2019;105(4):734-46.
20. Queisser A, Seront E, Boon LM, Vikkula M. Genetic Basis and Therapies for Vascular Anomalies. *Circ Res*. 2021;129(1):155-73.



Carine JM van der Vleuten, MD, PhD

Source: Radboud University Hospital

References

1. Leaute-Labreze C, Harper JL, Hoeger PH. Infantile haemangioma. *Lancet*. 2017;390(10089):85-94.
2. Hassanein AH, Mulliken JB, Fishman SJ, Alomari AI, Zurakowski D, Greene AK. Venous malformation: risk of progression during childhood and adolescence. *Ann Plast Surg*. 2012;68(2):198-201.
3. Zou Y, Qiao C, Lin X, Jin Y, Hua C, Yang X, et al. Clinical Course of Extracranial Arteriovenous Malformations. *J Craniofac Surg*. 2020;31(2):372-6.
4. Hassanein AH, Mulliken JB, Fishman SJ, Quatrano NA, Zurakowski D, Greene AK. Lymphatic malformation: risk of progression during childhood and adolescence. *J Craniofac Surg*. 2012;23(1):149-52.
5. Lee JW, Chung HY. Capillary Malformations (Portwine Stains) of the Head and Neck: Natural History, Investigations, Laser, and Surgical Management. *Otolaryngol Clin North Am*. 2018;51(1):197-211.
6. Kulungowski AM, Hassanein AH, Nose V, Fishman SJ, Mulliken JB, Upton J, et al. Expression of androgen, estrogen, progesterone, and growth hormone receptors in vascular malformations. *Plast Reconstr Surg*. 2012;129(6):919e-24e.
7. Ventejou S, Machet MC, Herbreteau D, le Touze A, Lorette G, Maruani A. Hormonal receptors in cutaneous vascular malformations: 51 cases. *Virchows Arch*. 2019;474(6):755-61.
8. Maclellan RA, Vivero MP, Purcell P, Kozakewich HP, DiVasta AD, Mulliken JB, et al. Expression of follicle-stimulating hormone receptor in vascular anomalies. *Plast Reconstr Surg*. 2014;133(3):344e-51e.

VASCERN

Summer School 2024



Are you ready to learn about rare vascular diseases from leading experts and patient advocates? Apply to the 1st VASCERN Summer School.

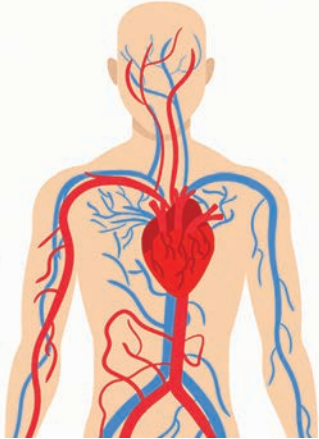
Online Course

February to May 2024

Onsite Course in Paris

September 23 to 28, 2024



Source: VASCERN

The inaugural VASCERN Summer School 2024 on rare vascular diseases with courses online and in Paris.

Complex Lymphatic Anomalies

Pär Gerwins, MD, PhD

The lymphatic system

The lymphatic system is a multifunctional vascular system that regulates tissue homeostasis (a self-regulation process to maintain stability) by transporting excess tissue fluid back into the bloodstream. It is responsible for the absorption of most dietary fats from the intestines, giving the lymph from the intestinal tract a milky appearance called chyle. The lymphatic system also serves an important immune function. Lymphatic fluid is transported in the lymph vessels where the smallest lymphatic capillaries allow the influx of excessive tissue fluid.

As lymph vessels continue more centrally in the body, they enlarge and are increasingly covered by smooth muscle cells that actively pump lymph forward by contracting. These collecting lymphatic vessels contain valves to ensure unidirectional forward flow and prevent lymph reflux. Lymph vessels from the legs, liver and intestines converge in a sac-like structure called the cisterna chyli, which is situated in front of the spine in the upper abdomen (Fig 1).

From the cisterna, chyle lymph is transported to the thoracic duct, then returned to the bloodstream via a lymphovenous connection at the left subclavian vein.

Given these functions, disruptions and anomalies in the lymphatic system can cause lymphatic leaks, lymphoedema (swelling of legs and arms), immunocompromise (having a weakened immune system) and malabsorption in the gut.

What are complex lymphatic anomalies?

Unlike common lymphatic malformations, which are focal congenital cystic lesions, the term complex lymphatic anomaly (CLA) refers to a group of four congenital conditions that are more extensive, diffuse in nature, and with high-risk features. Even though CLAs are different diseases, they have overlapping symptoms, imaging findings and complications.

Most patients develop symptoms early in life during childhood or adolescence. CLAs can affect the bones and/or visceral organs and are associated with pleural, pericardial, abdominal and sometimes skin effusions.

Patients might suffer from chronic pain, disability and acute complications (respiratory failure due to pleural effusions, bleeding due to coagulopathy, sepsis due to immune system failure and malnutrition due to lymph leakage into the intestines or as a result of prolonged fluid drainage).

The different types of CLAs

Gorham-Stout Disease

Gorham-Stout disease (GSD) is characterised by progressive bone destruction (osteolysis) with a surrounding soft tissue mass. There is no new bone formation, which might lead to the complete disappearance of the bones, which is why the disease is also known as vanishing or disappearing bone disease.

Diagnosis is mainly based on radiological imaging showing progressive loss of cortical bone. Magnetic resonance imaging (MRI) shows a soft tissue component with enhancement after intravenous contrast injection in the regions of active osteolysis.

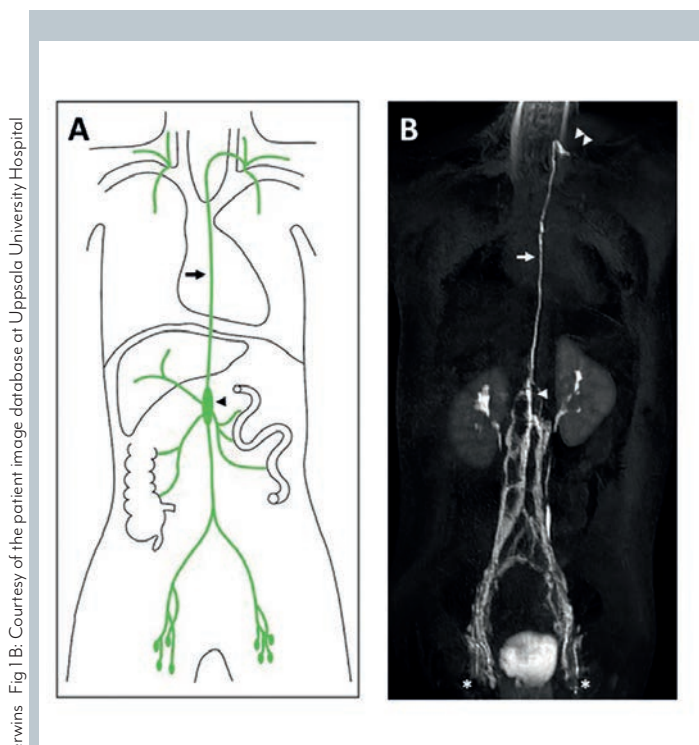


Fig. 1

(A) Schematic drawing of the lymphatic system. Lymph from the lower body, liver and intestines converge in the cisterna chyli (arrowhead) and is then transported through the thoracic duct (arrow) back into the blood by a connection to the subclavian vein. The right side of the body (head, arm, thorax) connects similarly to the right subclavian vein. (B) MR lymphangiography of a normal lymphatic system. Gd contrast is injected into lymph nodes in the groins (*) and appears bright delineating central lymphatic vessels including cisterna chyli (arrowhead), thoracic duct (arrow) and the inflow to the subclavian vein (double arrowheads). Contrast is excreted in the kidneys and bladder.

Source: Patients pictures database at Uppsala University Hospital

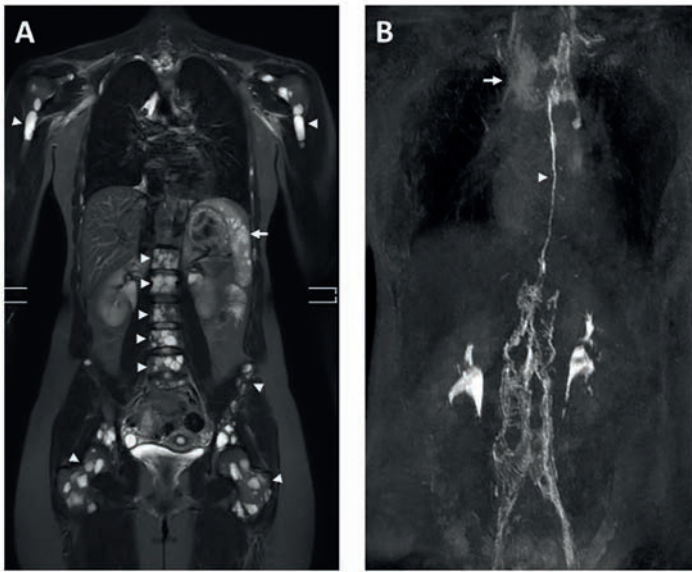


Fig. 2 Generalised lymphatic anomaly. (A) MRI with an STIR sequence shows multiple bright cystic lesions (arrowheads) in bones (humerus, spine, pelvis, femur) and spleen (arrow). (B) MR lymphangiography shows a normal thoracic duct (arrowhead) and reveals a leak in the upper thorax (arrow) that after aspiration was found to contain a chyle.

bones in the chest (ribs) can lead to pleural effusions where chylothorax (leakage and accumulation of lymphatic fluid in the chest cavity in the space between the lung and the chest wall) has been associated with a more severe outcome.

Generalised Lymphatic Anomaly

Generalised lymphatic anomaly (GLA) is characterised by multifocal lymphatic malformations that resemble common lymphatic malformations.

MRI detects lesions that can occur in different anatomical areas of the body: lesions in bone, liver, spleen, mediastinum and soft tissues are common (Fig 2A). In contrast to GSD, bone lesions are confined to the medullary cavity and do not cause osteolysis or destruction of cortical bone.

GLA also affects several bones in a non-contiguous pattern. The ribs, spine, pelvis, femur and humerus are the most commonly affected bones. Similar to GSD, patients with GLA might also have effusions causing ascites (build-up of fluid in spaces within the abdomen) and pleural fluid, often containing chyle (Fig 2B). Clinical symptoms and prognosis depend on the affected sites, with a decline in lung function being associated with a worse prognosis.

The lesions are characterised by thin-walled lymphatic vessels that grow and dilate into the cortical bone leading to bone breakdown.

GSD often progresses rapidly but might stabilise spontaneously. GSD mainly affects one bone, but can also affect several bones, often in a contiguous fashion. The maxillofacial bones, the vertebrae, the clavicles, the ribs and the pelvic girdle are the most commonly affected.

Symptoms are non-specific and include pain, swelling, muscle weakness, skeletal deformity, pleural and pericardial effusion, and spinal instability. The pain can be caused by pathological fractures following minor trauma or it can be atraumatic. Involvement of the

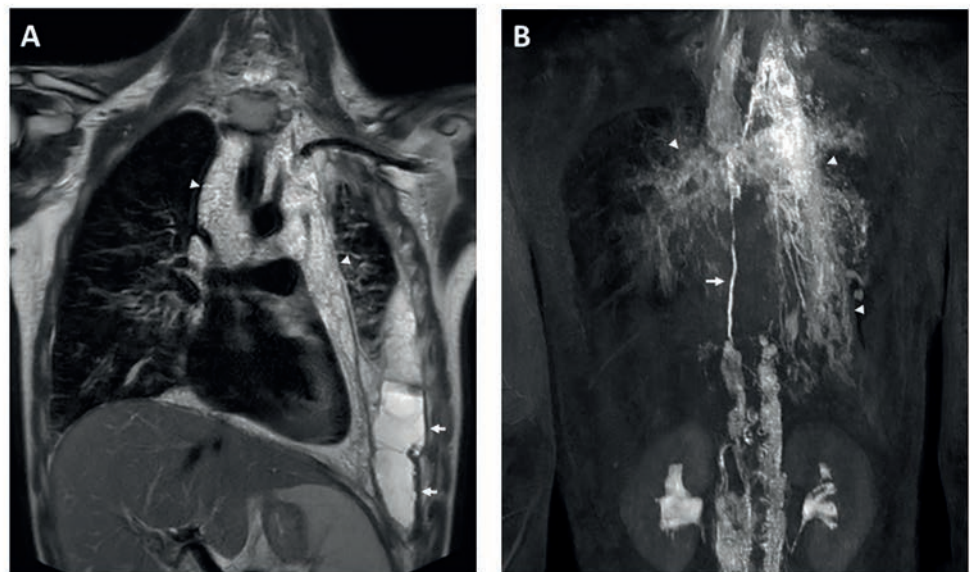


Fig. 3 Kaposiform lymphangiomatosis. (A) MRI with T2 sequence shows a soft tissue mass in the mediastinum (arrowheads) and pleural effusion (arrows). (B) Dynamic MR lymphangiogram with a normal thoracic duct (arrow) but with perihilar reflux of contrast and leakage into the mediastinum and pleura (arrowheads).

Kaposiform lymphangiomatosis

Kaposiform lymphangiomatosis (KLA) is an aggressive disease with high morbidity and mortality.

It is characterised by soft tissue masses that almost always involve the thoracic cavity and the mediastinum (Fig 3A). Typically, the soft tissue in the mediastinum extends into the hila and along the bronchovascular bundle. The soft tissue in KLA lesions has abnormal lymphatic channels and specific cells called spindled lymphatic endothelial cells. Platelet trapping is sometimes seen. MR lymphangiography (a test that visualises the lymphatic vessels) might show an abnormal thoracic duct, dilated central lymphatic vessels and signs of reflux (Fig 3B).

In addition, KLA can also involve the abdominal cavity, pelvis, bone, spleen and muscle. Bone lesions are osteolytic (breakdown of bone) but do not affect the outer bone cortex, which gives bones their strength (cortex sparing). They can affect several bones in a non-contiguous manner, with vertebrae being the most common bone affected. Symptoms are mainly due to lesions in the thorax, such as dyspnoea, cough and chest pain.

Pleural effusions are common and can be clear fluid but contain blood and/or chyle. Coagulopathy is common and manifests as thrombocytopenia (low platelet count) and hypofib-

rinogenemia (abnormal deficiency of fibrinogen in the blood; fibrinogen is a protein that helps blood clot). It is likely to cause bleeding, including haemorrhagic pleural effusions. Angiopoietins are biomarkers with increased levels in the blood, and angiopoietin-2 has been used to monitor disease activity.

Central Conducting Lymphatic Anomalies

In central conducting lymphatic anomalies (CCLA), there is impaired motility in the lymphatic vessels or dysfunction in the terminal portion of the thoracic duct and/or cisterna chyli due to functional or mechanical obstruction.

This results in lymphatic fluid stasis, enlargement of lymphatic channels, reflux and leaks (Fig 4A). Manifestations and symptoms of stasis and reflux include chylothorax, pericardial effusion, chylous ascites, lymphangiectasia (dilated lymphatic vessels), protein-losing enteropathy (causing low blood albumin levels), lymphoedema, cutaneous vesicles and superficial chylous leaks.

Diagnosis is based on MR lymphangiography showing enlarged lymphatic vessels with reflux and/or absence of normal flow from the thoracic duct into the subclavian vein (Fig 4B). Lab tests might show low albumin levels and immunoglobulin G due to loss of lymphatic fluid to the intestines.

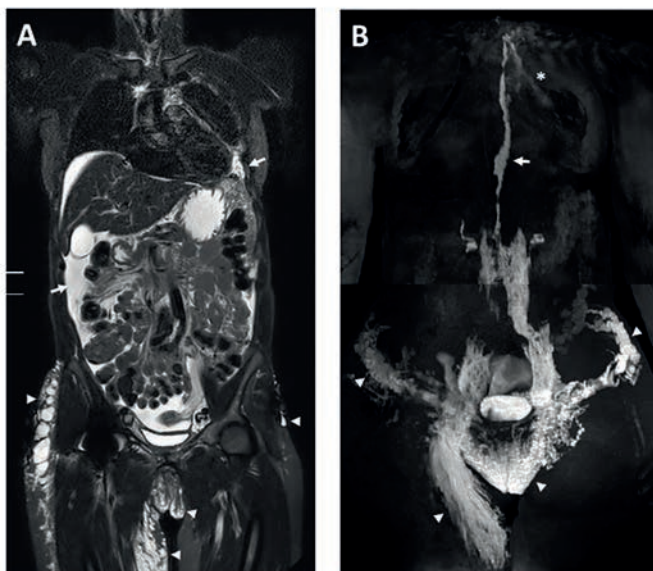


Fig. 4

Central conducting lymphatic anomaly. (A) MRI with STIR sequence shows ascites and pleural effusion (arrows). Analysis of aspirated fluid showed chyle. There is an increased fluid signal in vessel-like structures in subcutis in the left leg, labia and lower abdomen (arrowheads). (B) MR lymphangiography shows reflux to subcutis in the labia, upper leg and in the flanks (arrowheads). The thoracic duct is widened and tortuous (arrow) with reflux to the left thorax (*) as a sign of impaired/blocked emptying to the subclavian vein.

What causes CLA

The causes of CLAs are not fully understood. CLAs are sporadic diseases that are not inherited. However, an increasing number of somatic gene mutations are continuously being identified in affected tissues.

These mutations cause activation of signalling pathways within cells, with mutations in signalling proteins in the PI3K/AKT and the RAS/RAF/MEK/MAPK pathways being the most common.

Activating mutations of the PIK3CA are known to cause common lymphatic malformations and have also been identified in GLA.

Mutations in the RAS-MAPK pathway have been found in GSD (KRAS), KLA (NRAS) and CCLA (ARAF).

In addition, mutations in the signalling protein CBL have been found in KLA and EPHB4 in CCLA.

Treatment of CLAs

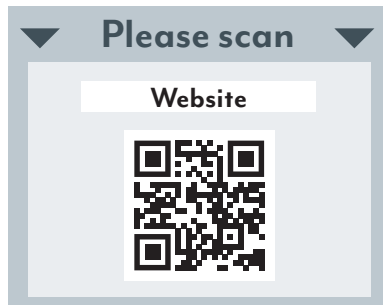
Although there is no curative treatment for CLAs, there are treatments that aim to stabilise the disease and reduce complications.

Pharmacological options include steroids, interferons, bisphosphonates (for bone lesions) and sirolimus (rapamycin). Novel inhibitors of PI3K/AKT and MEK are currently being investigated.

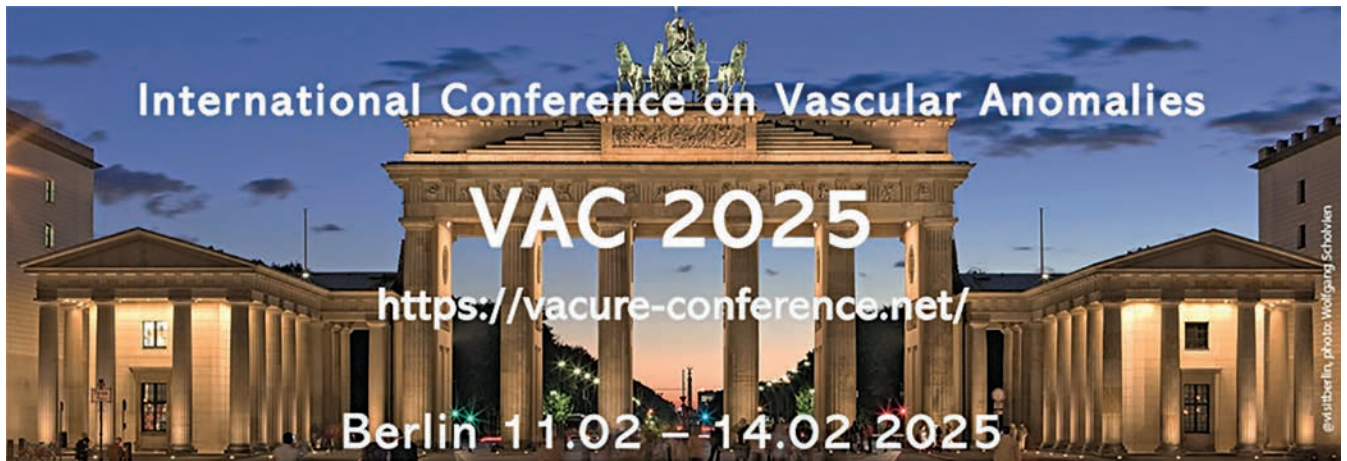If the terminal portion of the thoracic duct is absent or otherwise compromised, it can be surgically reimplanted by lympho-venous

anastomosis. Sclerotherapy of lymphatic cysts and endovascular embolization of lymphatic leaks and reflux can give substantial symptom relief.

Compression garments are useful when peripheral lymphoedema or swelling is present. Orthopaedic surgery may be needed to stabilise the skeleton in patients with bone destruction. Managing complex lymphatic anomalies is often challenging, requiring a multimodal and interdisciplinary approach.



Pär Gerwins, MD, PhD, Professor
 Interventional Radiology
 Uppsala University Hospital
 751 85 Uppsala
 Sweden
 Phone: +46(0)739848207
 ○ par.gerwins@akademiska.se
 ○ www.akademiska.se



Translating basic research into new therapies

The latest developments in vascular anomalies research, meet the world experts, set-up new collaborations, expand your network and many more... *See you in Berlin!*



TESTIMONIAL A Lymphatic Malformation Made Erwin Become a Tech Savvy

Erwin Oudshoorn (HEVAS)

Erwin was born in Amstelveen, close to Amsterdam in the Netherlands, on 20 October 1987 with a lymphatic malformation. His malformation was located in the jaws area, and it caused his jaws to fuse together. After his birth, Erwin spent 15 months in intensive care at the VU University Amsterdam where they saved his life, yet they had to place a cannula and had to remove part of his tongue. This and the malformation itself, strongly affected his ability to speak and be understood. Despite this abnormality, Erwin has managed to function very well in society and does not see himself as someone with a disability, largely due to today's modern technology.

During his childhood, Erwin underwent numerous operations, laser treatments and injections of OK 432 at the University Medical Hospital in Groningen. His cannula was removed in 1996, but Erwin suffered from sleep apnoea, which was soon resolved by sleeping on a continuous positive airway pressure (CPAP) machine. But life took an unexpected turn on 1 April 2001 when, at the age of 14, a choking incident required a return to intensive care and having to put a cannula back again. During his recovery, Erwin was taught by two students how to design a HTML page. This turned into a "building websites" hobby that later on developed into a successful media company. As, in between, Erwin followed his interest in (online) marketing and sales and in 2005 he obtained three diplomas at the Grafisch Lyceum in Utrecht: Graphic and multimedia layout, All-round DTP and Interactive Media Design.

In 2007, Erwin's life took a positive turn when, through the HEVAS patient organisation, he got in touch with American Professor Milton Waner from New York.

He was treated in Germany, near Berlin, an average of three times a year, making progress step by step through laser treatments and operations. Major operations, including a jaw surgery in 2010 and a 12-hour muscle transplant in 2014, gave Erwin the ability to smile, something previously unimaginable.

A second jaw surgery was required to set his upper jaw forward and his lower jaw backwards, leading to a challenging recovery period during which Erwin's jaws were fixed together for eight weeks. The decision of where to have the operation - Athens or Utrecht - was eventually made in favour of UMC Utrecht under the care of Dr van Es, the Netherlands' leading oral surgeon.

The operation was very successful and made a huge difference. During Erwin's recovery, he kept active and developed the Talkie app with which he could make himself understood. Once again a little hobby project became a means of communication for people who cannot speak. During this period he also created a dating site called Capido for people with physical/mental disabilities.

In 2018, after the team made it clear that there wasn't much more they could do for him after his nearly 40th surgery in Germany, Erwin decided to finish with surgery.

He continues to follow the latest developments in the medical field, he tried sirolimus but had no effect. In 2023, he was invited to take part in the worldwide apelisib trial (EPIK-P2). After some time, Erwin noticed a slight decrease in the volume of his LM, which gave him some hope.

Erwin channels his energy into his app and dating website. He launched the app version of Capido in the Netherlands in 2021, which attracted attention from various media outlets. The dating platform will also be launched in Germany early 2024.



Erwin Oudshoorn

Diagnostics and Management of Peripheral Arteriovenous Malformations

Dr. Annouk Bisdorff Bresson, MD, Dr. Rune Andersen, MD

What is an arteriovenous malformation?

A normal blood vessel network consists of arteries supplying the body tissues with oxygen (O²) and nutrients, and veins transporting carbon dioxide (CO²) rich blood back to the heart. From the heart, the blood travels to the lungs, where CO² from the tissues is exchanged for O² from the air we breathe in, carried by red blood cells.

In the lungs, as in other tissues of the body, the capillaries constitute the connections between the thinnest branches of the arteries (arterioles) and the thinnest branches of the veins (venules) (Figure 1 A). An arteriovenous malformation (AVM) is anatomically characterised by the absence of normal capillaries (Figure 1B, 1C), decreasing the normal resistance for blood passage through the tissue, thereby increasing the speed of blood transport from the arterial to the venous side. For this reason, AVMs are often called high-flow vascular malformations. AVMs constitute abnormal communications between arteries and veins called arteriovenous shunts (AV shunts). Like short circuits in an electric system, AV shunts produce an “excess of energy” in the arteries and veins of the AVM. This excess of energy causes vessel lengthening and dilatation of both types of vessels, especially near the AV shunts. As a result, these vessels become tortuous and dilated, forming a nidus (Figure 1B, 1C).

AVMs are benign, congenital, high-flow malformations and appear during the early gestational period^{1,2,3}. Often clinical-

ly invisible in early childhood, these lesions grow proportionally with the body and become symptomatic after puberty (although in some cases they can become symptomatic earlier, even in early childhood).

Hormonal changes during puberty and/or pregnancy might trigger the growth of these vascular malformations. Bodily traumas, including surgery, may also trigger growth by inducing upregulation of blood vessel growth factors.

Most AVMs are not hereditary but sporadic, meaning that they are caused by a mutation in the genes of the foetus itself. Recent studies have identified some of the genetic mutations^{4,5,6}. There are rare familial forms of AVMs, usually associated with other anomalies in a syndromic context such as hereditary haemorrhagic telangiectasia (HHT or Rendu-Osler disease), capillary malformation-arteriovenous malformation syndrome (CM-AVM) and Cowden syndrome (PTEN). These are due to germline mutations, meaning that the gene responsible for the malformation has been inherited from one or both parents.

What are the symptoms and problems with AVMs?

AVMs may not cause any symptoms or problems for the individual, or they may cause physical signs such as redness and increased skin temperature. Swelling and pulsation may or may not cause discomfort and pain. Sometimes destruction of adjacent tissues leads to skin ulceration, bleeding episodes, and exceptionally, cardiac high-output failure.

The Clinical Schobinger Classification (Table 1) helps to assess a patient’s evolution and to guide therapeutic decisions in the expert multidisciplinary group of vascular anomalies.

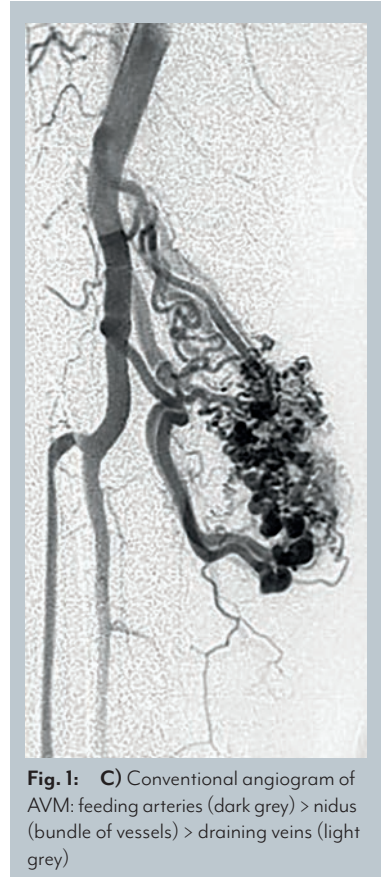


Fig. 1: C) Conventional angiogram of AVM: feeding arteries (dark grey) > nidus (bundle of vessels) > draining veins (light grey)

Source: Courtesy of the patient image database at Oslo University Hospital

Source: Massoni et al., J. Vasc. Anomalies, 2021. DOI: 10.1097/JOVA.000000000000007.

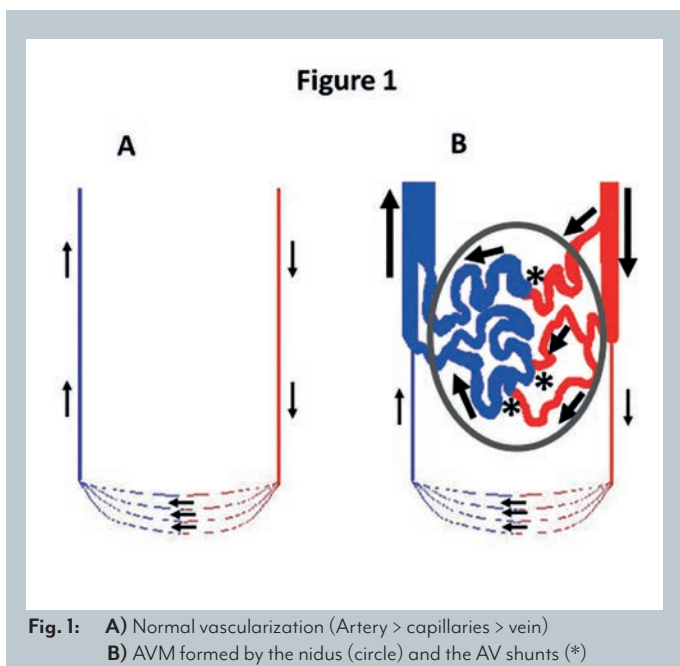


Fig. 1: A) Normal vascularization (Artery > capillaries > vein)
B) AVM formed by the nidus (circle) and the AV shunts (*)

Stage	Features
I	Cutaneous blush/warmth
II	Bruit, audible pulsations, expanding lesions
III	Pain, ulceration, bleeding, infection
IV	Cardiac failure

Table 1

Schobinger classification. (Schöbinger R. 'Schöbinger Classification of Arteriovenous Malformations.' Presented at the International Society for the Study of Vascular Anomalies Congress, Rome, Italy, June 1996.)

Diagnosis of AVMs. How do we find and characterise them?

In lesions that are accessible to physical examination, the clinical past medical history and physical findings, together with typical radiological findings, are usually sufficient for diagnosis. Clinical signs include thrill, pulsatile mass, increased skin temperature and bruit (a murmur). AVMs may sometimes cause pain and swelling. The veins draining blood from the AVMs are enlarged and strutting and may be easily visible in the skin (Figure 2). These pulsatile lesions are sometimes associated with a reddish cutaneous stain = "false port wine stain".

Occasionally, a large AVM may cause an excessive workload on the heart, requiring cardiac ultrasound examination and treatment to reduce this burden.

The key medical tests to be conducted are:

Doppler ultrasound is a non-invasive imaging method to quickly confirm the high-flow nature of the lesion, provide an accurate AVM mapping and evaluate AVM flow velocities. AVMs show low resistance flow as compared to normal tissue (Figure 3). This test is often used to follow up an AVM.

Magnetic resonance imaging (MRI) is the most helpful tool to evaluate the location, size and extension of the AVM into soft tissues such as muscles, cellular spaces, and intraosseous components. MRI will show the absence of MR signals in the high-flow vessels, the so-called "flow void sign" (Figure 4), and the different tissue involvement.

Computed tomography imaging (CT) with contrast injection may be very helpful in describing bone involvement and performing 3-D dimensional visualisation of the blood vessels involved (Figure 5).

If the diagnosis remains unclear after ultrasound, computed tomography and/ or MRI, conventional catheter angiography (Figure 1c) is the preferred investigative procedure to best characterise flow dynamics, vessel size and the complexity of the vascular architecture. Catheter angiography requires the puncture of an artery (usually in the groin) and the insertion of a 1 to 2-mm thick plastic tube, through which a thin catheter is then advanced and directed into the artery that needs to be visualised. A contrast agent is injected, and a cine x-ray is taken to obtain a film of the contrast material when it runs through the vessels and malformation (Figure 1c). Catheter angiography is usually mandatory if embolization or resection of the AVM is planned.

Treatment considerations and treatment

Patients presenting with extracranial AVMs need to be taken care of in a complete and experienced multidisciplinary vascular anomalies team. Questions that need to be answered are: Who needs to be treated and why? How should the AVM be treated? When should it be treated, and by whom?

A thorough clinical examination (Schobinger staging, Table 1) and precise imaging correlation (US, MRI and/or CT imaging and/or Angiograms) are mandatory before any treatment decision is discussed with the patient. Peripheral AVMs are challenging to treat, with the potential for recurrence after partial or non-targeted treatments, and this must be communicated to the patient.

The mainstay of therapy is either medical treatment management (clinical follow-up and compression garments, beta-blockers, targeted medical therapy) or more invasive treatments such as endovascular embolization / direct puncture, and /or surgical AVM excision.

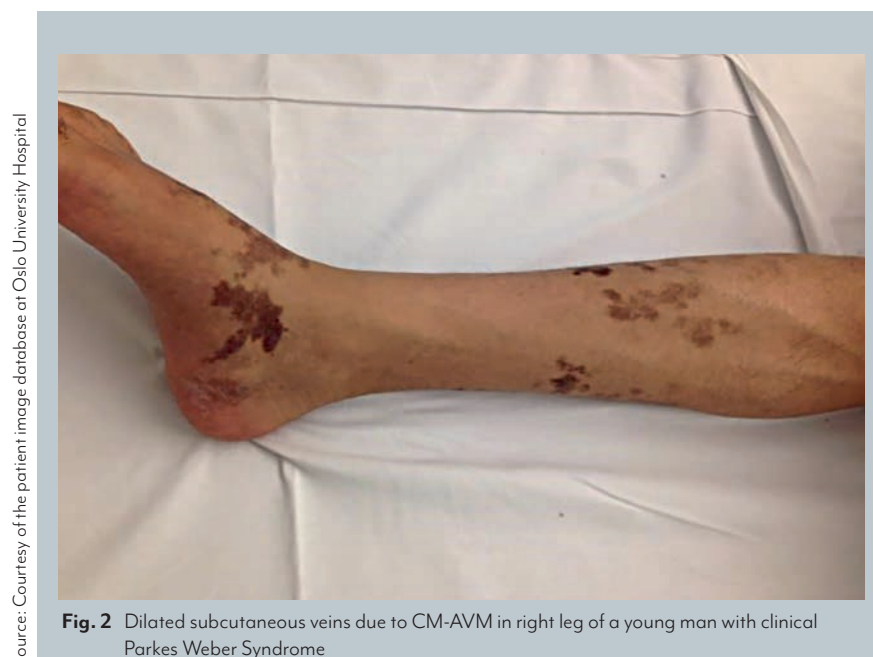

Fig. 2 Dilated subcutaneous veins due to CM-AVM in right leg of a young man with clinical Parkes Weber Syndrome

Source: Courtesy of the patient image database at Oslo University Hospital

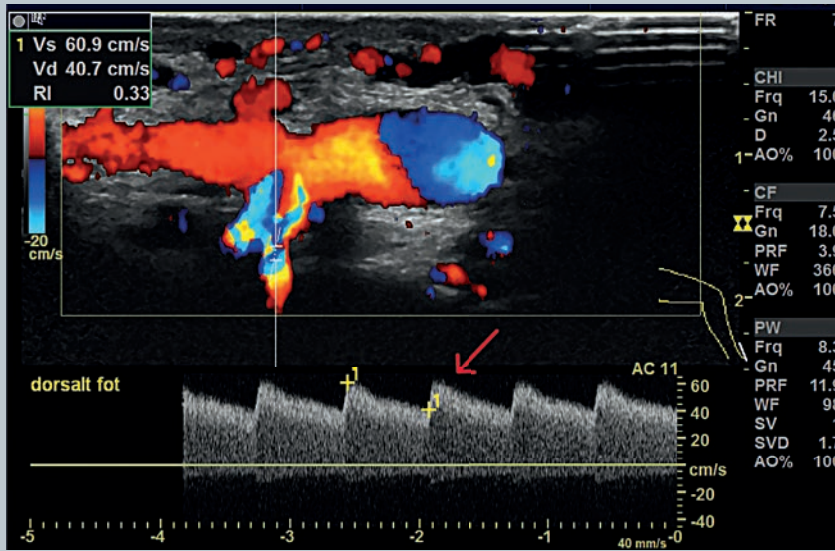


Fig. 3 Ultrasound image of AVM showing low resistance flow on Doppler-examination (arrowhead)

Patients with Schobinger stage 1 who present with few symptoms should be treated by medical means: clinical follow-up with beta-blocker drug treatment may be considered (team-dependent) to reduce the flow velocities in the AVMs, and elastic compression garments to avoid venous skin complications due to venous hypertension.

Schobinger stage 2 to 4 patients with clinical progression and/or recurrent bleeding episodes can benefit from either medical treatment, targeted embolization techniques and/or excision surgery depending on AVM location, size and imaging characteristics. It is very important to recognise that a complication of treatment may be as symptomatic as the complication of the AVM itself. Treatment must be individualised, discussed on a case-to-case basis, and carried out in an experienced multidisciplinary team setting with physicians who are aware of the complexity and possible treatment complications of these lesions.

Surgical resection is favourable when possible, especially when complete AVM removal may be obtained without harming important surrounding structures. However, interventional radiology techniques have dominated AVM treatment over the last 20 years. (8,9,10). Technical progress in arterial, venous, and percutaneous vascular approaches, and improvement in endovascular catheterization material and embolic agents have resulted in reduced numbers of post-treatment failures. The number of treatment sessions has been reduced. Precise AVM vessel architecture analysis has an important role in deciding how and what to treat. The Yakes classification (Figure 6) may be helpful in decision-making.

It is very important to avoid surgical ligation or coil-/plug embolisation of the arteries feeding the AVM. This is contraindicated if you are unable to occlude the entire venous runoff from the AVM. Due to the complexity of most AVMs, and the possible (potentially large) negative implications of a wrong-

ful treatment, embolisation and surgery of AVMs should only be done by expert radiologists and surgeons working within or in coordination with an expert multidisciplinary centre.

A previous study of recurrence after treatment (11) showed that resection (with or without embolization) had a lower recurrence rate and a longer time to recurrence compared with embolization alone.

However, this study included extracranial head-neck AVM and other areas without accurately identifying the tissue location of the nidus and without post-procedural evaluation of residual AVMs.

Future treatment options. Medical therapy alone or in combination

Most AVMs are sporadic, and recent studies have started to elucidate the genetic basis of these lesions with the identification of somatic variants in genes of the RAS/MAPK signaling pathway. MAP2K1 and KRAS genes are found in more than 60% of patients. Most of these mutations are also identified in malignant tumours, where they play a "driver" role in

Source: Courtesy of the patient image database at Oslo University Hospital

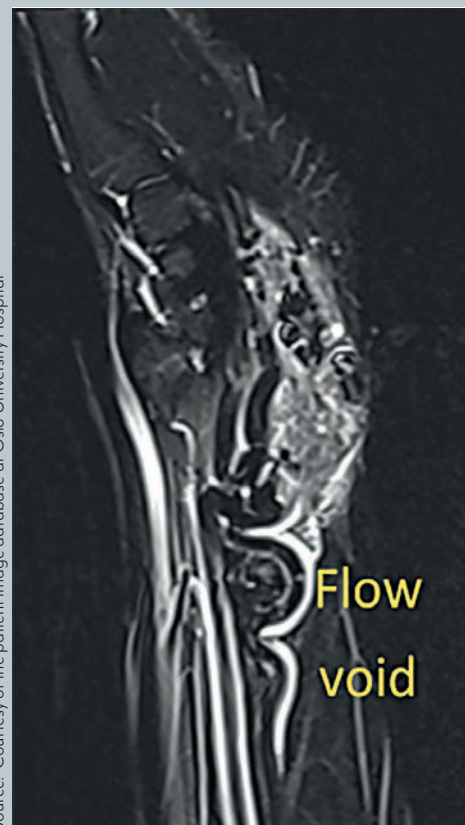


Fig. 4 MR image of AVM in forearm. Flow void indicating fast-flow lesion.

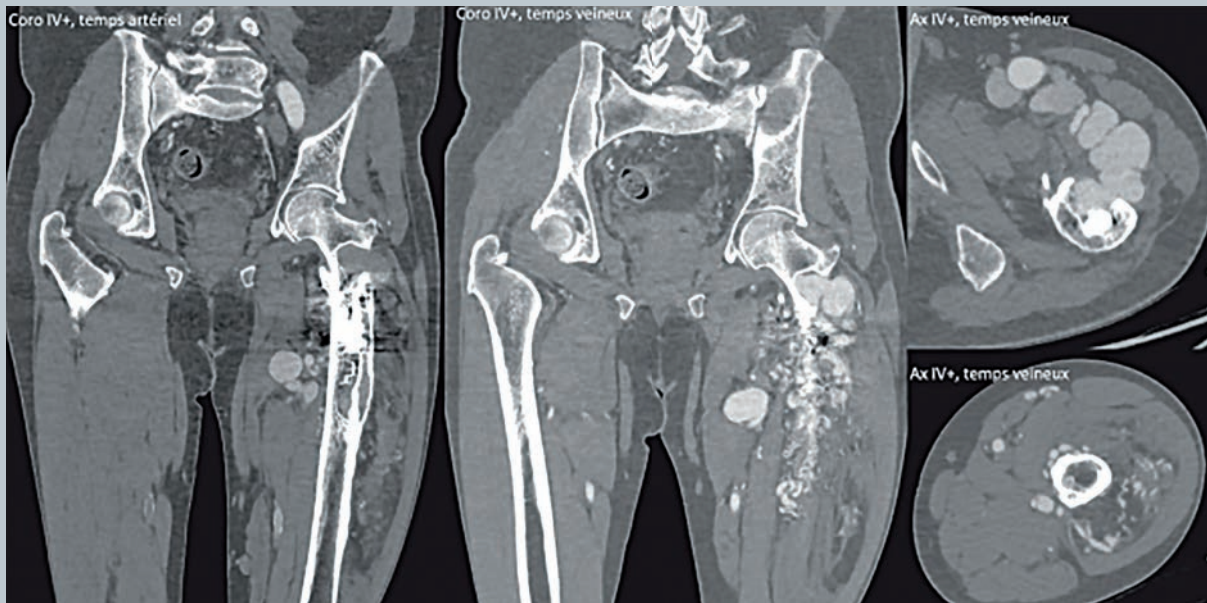


Fig. 5 Contrast enhanced CT angiography showing AVM in left hip region involving femoral bone destruction.

tumour growth and for which targeted therapies (MEK inhibitors) have already been developed and are widely used in oncology. Given the similarity of the targets, these targeted therapies could offer a new therapeutic strategy for clinicians managing patients with AVMs.

Two recent case reports have shown the efficacy of a MEK inhibitor (trametinib) in extracranial AVMs. Lekwuttikarn et al. reported a case of an extracranial MAP2K1-mutated dorsal AVM in an 11-year-old female patient, and Edwards et al. (12-14) described the impact of trametinib (Mekinist) in the management of a syndromic form of AVMs with a KRAS mutation.

The use of sirolimus (15) has become the current off-label standard of care for lymphatic and venous malformations, although vascular anomalies are not yet an approved indication for sirolimus. Phase-3 trials are ongoing, but initial learnings have shown poor efficacy of sirolimus in the treatment of extracranial arteriovenous malformations.

In some pilot studies, the anti-angiogenic effect of thalidomide (known as Contergan, Thalomid, Softenon) has shown clinical improvement in patients treated for epistaxis in HHT patients, and other teams have used it as an off-label use in the treatment of superficial AVMs (17). Recently, Laurence Boon et al.

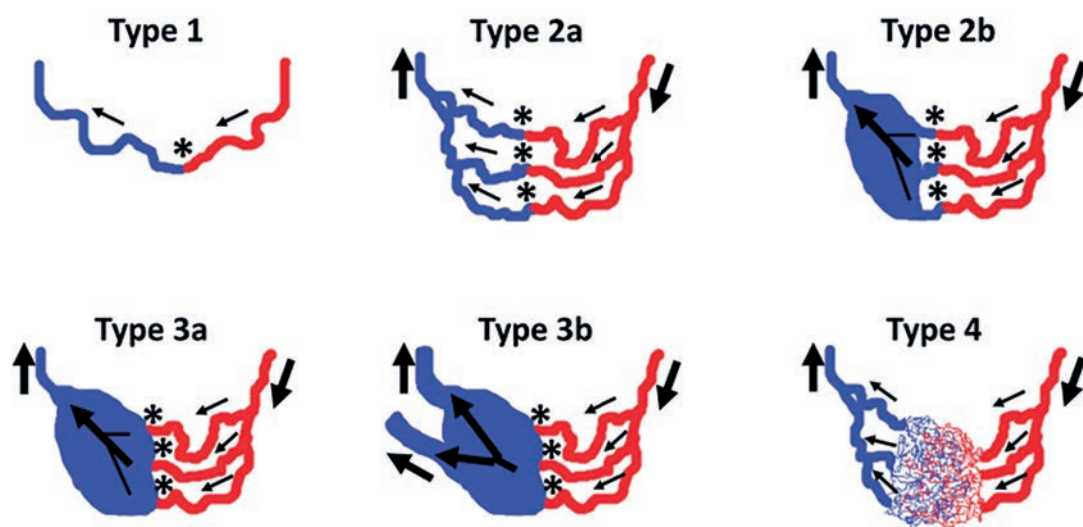


Fig. 6: Yakes classification: Schematic overview of different types of angioarchitecture in AVMs relevant for planning of treatment.

1: Direct single AVM shunt.

2a: Multiple arteries/arterioles connecting to a typical "nidus" interconnecting vascular tubular structures that then drain into out-flow veins.

2b: Same as Type 2a except the "nidus" drains into an aneurysmal vein with single outflow.

3a: Multiple in-flow arterioles shunting into an aneurysmal vein that has a single vein out-flow. AV-shunts are in wall of vein aneurysm.

4: Multiple in-flow arteries/arterioles shunting with innumerable micro AVM shunts and multiple out-flow veins that diffusely infiltrate the affected tissue.

published a very interesting case report study of thalidomide therapy in patients with severe arteriovenous malformations (16).

In this context, there is a strong rationale to evaluate the clinical safety and efficacy of both thalidomide and MEK inhibitors such as trametinib in patients with AVMs. Many other candi-

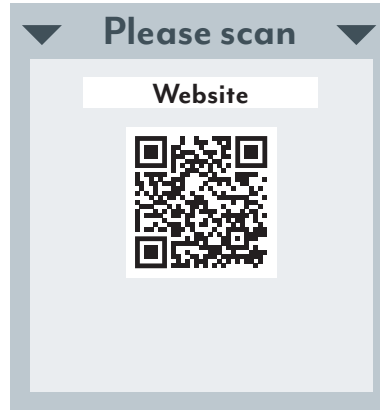dates for systemic and hopefully topical medical treatment will occur in the future, but for now, there are obviously concerns regarding side effects in both the short and long run.

Acknowledgements: Vascular Anomalies Group of the Lariboisière Hospital and in particular C Massoni- Laanegh, MD; F El Sissy, MD; M Eyries and C Laurian.

Photo: Annouk Bisdorff Bresson



Dr. Annouk Bisdorff Bresson, MD

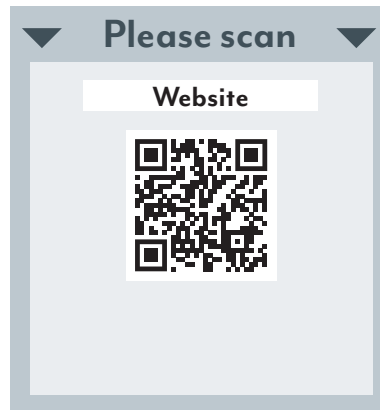


Annouk Bisdorff Bresson, MD
 Hôpital Lariboisière APHP
 2 rue d'Ambroise Paré
 75010 Paris
 France
 Vascular Anomalies Clinic
 Department of Neuroradiology
 ● annouk.bisdorff@aphp.fr
 ● <https://hopital-lariboisiere.aphp.fr/>

Photo: Rune Andersen, MD



Dr. Rune Andersen, MD



Rune Andersen, MD
 Oslo University Hospital
 Section Interventional radiology
 Department of Radiology and
 Vascular Anomaly Group
 Rikshospitalet
 Sognsvannsveien 20
 0027 Oslo (Norway)
 ● randerse@ous-hf.no
 ● www.oslo-universitetssykehus.no/

References

- Mulliken JB, Glowacki J. Classification of pediatric vascular lesions. *Plast Reconstr Surg.* 1982 Jul;70(1):120-1. PMID: 7089103.
- Wassef M, Blei F, Adams D, Alomari A, Baselga E, Berenstein A, Burrows P, Frieden IJ, Garzon MC, Lopez-Gutierrez JC, Lord DJ, Mitchel S, Powell J, Prendiville J, Vikkula M; ISSVA Board and Scientific Committee. Vascular Anomalies Classification: Recommendations From the International Society for the Study of Vascular Anomalies. *Pediatrics.* 2015 Jul;136(1):e203-14. doi: 10.1542/peds.2014-3673. Epub 2015 Jun 8. PMID: 26055853.
- Lee BB, Baumgartner I, Berlien HP, Bianchini G, Burrows P, Do YS, Iancev K, Kool LS, Laredo J, Loose DA, Lopez-Gutierrez JC, Mattassi R, Parsi K, Rimon U, Rosenblatt M, Shortell C, Simkin R, Stillo F, Villavicencio L, Yakes W; International Union of Angiology. Consensus Document of the International Union of Angiology (IUA)-2013. Current concept on the management of arterio-venous management. *Int Angiol.* 2013 Feb;32(1):9-36. PMID: 23435389.
- Burrows PE. Angioarchitecture of Hereditary Arteriovenous Malformations. *Semin Intervent Radiol.* 2017 Sep;34(3):250-257. doi: 10.1055/s-0037-1604298. Epub 2017 Sep 11. PMID: 28955114; PMCID: PMC5615386.
- Couto JA, Huang AY, Konczyk DJ, Goss JA, Fishman SJ, Mulliken JB, Warman ML, Greene AK. Somatic MAP2K1 Mutations Are Associated with Extracranial Arteriovenous Malformation. *Am J Hum Genet.* 2017 Mar 2;100(3):546-554. doi: 10.1016/j.ajhg.2017.01.018. Epub 2017 Feb 9. PMID: 28190454; PMCID: PMC5339083.
- Nguyen HL, Boon LM, Vikkula M. Vascular Anomalies Caused by Abnormal Signaling within Endothelial Cells: Targets for Novel Therapies. *Semin Intervent Radiol.* 2017 Sep;34(3):233-238. doi: 10.1055/s-0037-1604296. Epub 2017 Sep 11. PMID: 28955112; PMCID: PMC5615384.
- Gilbert P, Dubois J, Giroux MF, Soulez G. New Treatment Approaches to Arteriovenous Malformations. *Semin Intervent Radiol.* 2017 Sep;34(3):258-271. doi: 10.1055/s-0037-1604299. Epub 2017 Sep 11. PMID: 28955115; PMCID: PMC5615391.
- Soulez G, Gilbert Md Frcep P, Giroux Md Frcep MF, Racicot Md Frcep JN, Dubois J. Interventional Management of Arteriovenous Malformations. *Tech Vasc Interv Radiol.* 2019 Dec;22(4):100633. doi: 10.1016/j.tvir.2019.10.0633. Epub 2019 Oct 16. PMID: 31864530.
- Park KB, Do YS, Kim DI, Kim YW, Park HS, Shin SW, Cho SK, Hyun DH, Choo SW. Endovascular treatment results and risk factors for complications of body and extremi-

- arteriovenous malformations. *J Vasc Surg.* 2019 Apr;69(4):1207-1218. doi: 10.1016/j.jvs.2018.07.051. PMID: 30905365.
- Chelliah MP, Do HM, Zinn Z, Patel V, Jeng M, Khosla RK, Truong MT, Marqueling A, Teng JMC. Management of Complex Arteriovenous Malformations Using a Novel Combination Therapeutic Algorithm. *JAMA Dermatol.* 2018 Nov 1;154(11):1316-1319. doi: 10.1001/jamadermatol.2018.3039. PMID: 30326494; PMCID: PMC6248124.
- Liu AS, Mulliken JB, Zurakowski D, Fishman SJ, Greene AK. Extracranial arteriovenous malformations: natural progression and recurrence after treatment. *Plast Reconstr Surg.* 2010 Apr;125(4):1185-1194. doi: 10.1097/PRS.0b013e3181d18070. PMID: 20335868.
- Dekeuleneer V, Seront E, Van Damme A, Boon LM, Vikkula M. Theranostic Advances in Vascular Malformations. *J Invest Dermatol.* 2020 Apr;140(4):756-763. doi: 10.1016/j.jid.2019.10.001. PMID: 32200879.
- Lekwuttikarn R, Lim YH, Admani S, Choate KA, Teng JMC. Genotype-Guided Medical Treatment of an Arteriovenous Malformation in a Child. *JAMA Dermatol.* 2019 Feb 1;155(2):256-257. doi: 10.1001/jamadermatol.2018.4653. PMID: 30566190; PMCID: PMC7186908.
- Nicholson CL, Flanagan S, Murati M, Boull C, McGough E, Ameduri R, Weigel B, Maguiness S. Successful management of an arteriovenous malformation with trametinib in a patient with capillary-malformation arteriovenous malformation syndrome and cardiac compromise. *Pediatr Dermatol.* 2022 Mar;39(2):316-319. doi: 10.1111/pde.14912. Epub 2022 Jan 10. PMID: 35014097.
- Gabeff R, Boccarda O, Soupre V, Lorette G, Bodemer C, Herbreteau D, Tavernier E, Maruani A. Efficacy and Tolerance of Sirolimus (Rapamycin) for Extracranial Arteriovenous Malformations in Children and Adults. *Acta Derm Venereol.* 2019 Nov 1;99(12):1105-1109. doi: 10.2340/00015555-3273. PMID: 31386166.
- Boon, L.M., Dekeuleneer, V., Coulie, J. et al. Case report study of thalidomide therapy in 18 patients with severe arteriovenous malformations. *Nat Cardiovasc Res* 1, 562–567 (2022). <https://doi.org/10.1038/s44161-022-00080-2>
- Invernizzi R, Quaglia F, Klersy C, Pagella F, Ornati F, Chu F, Matti E, Spinozzi G, Plu-mitallo S, Grignani P, Olivieri C, Bastia R, Bellistri F, Danesino C, Benazzo M, Balduini CL. Efficacy and safety of thalidomide for the treatment of severe recurrent epistaxis in hereditary haemorrhagic telangiectasia: results of a non-randomised, single-centre, phase 2 study. *Lancet Haematol.* 2015 Nov;2(11):e465-73. doi: 10.1016/S2352-3026(15)00195-7. Epub 2015 Oct 27. PMID: 26686256; PMCID: PMC4839500.

TESTIMONIAL Life and Choices with an Arteriovenous Malformation

Coraline


This is my story, of living with an arteriovenous malformation in my right cheek since birth.

I can't remember how long I have been aware of my AVM. Sometimes I even think that as a child I wasn't aware I had anything...

Yet the reality is that my parents took me to a specialist once a year. Then, in 2011 when I was 25, my life changed and I became very aware of my AVM, and it impacted my daily life.

At that time, I was going through some pretty stressful times which lasted for a while. And that's when I started to feel very intense, unbearable pain, which often ended in me feeling faint.

The emergency services regularly came to help and get me from my workplace. I have been unable to work since August 1, 2011.



Source: Coraline

Every week, I went to see the specialist who had been following me for years. I had treatments that turned me into a zombie. One day, my doctor even told me that the pain was only in my head! But I was really in pain... horrible pain... like electric shocks... as if someone was squeezing my cheek until it bursts.

That specialist never wanted to operate because it was too dangerous.

I met other doctors in other cities in France but I never found anyone who would treat me or relieve my pain; or anyone who would listen to me. Until the day my mom discovered the Cliniques Universitaires Saint Luc and Professor Laurence Boon.

That was when my ordeal began to ease. It was an incredible encounter that changed the course of my life. I think she is incredible! Prof Boon immediately told me that she could treat me although not cure me.

Following our meeting, Professor Boon kindly invited me to the conference organised for the St Luc's centre's 20th anniversary. There, I was finally able to understand what I had: a disease and it was rare.

It was also there that I knew I wasn't alone and that I would never be alone again; because I joined the VASCAPA patient organisation that was just starting out.

After scans and MRIs, together we began a treatment process. Prof Hammer, performed nine embolisations in seven years. I tried several treatments, each of which worked relatively well. In the meantime, my partner and I wanted to have a child. I had always been told that it would be difficult because there is a high risk of the disease worsening.

But the desire was stronger than the fear. The hardest part of my pregnancy was the 45 extra kilos I gained. I was in pain, yes, but I was going to be a mother. During my pregnancy, I also had to stop my treatment because the two were not compatible.

My son Marcel turned eight in April and he is healthy. He does not have my disease, as my AVM is not hereditary.

In 2019, I set up my own business. I make beautiful jewellery for women every day. I manage my website, orders, and shipments. 26k people follow me on social media.

I work at my own pace. This allows me to manage my illness and keep working, because at last I can make a living from my passion, and I am lucky enough to be able to look after my son.

Sure, people often look at me a little longer on the street, sometimes even make fun of me. They ask me if I have had my wisdom teeth removed. But every day, I live, I have fun with my son, with my partner, I travel, I sing, I dance and above all, I laugh! There are good days and bad days... but I always make sure I have a great day.

A few years ago, Professor Boon suggested a solution to cure me. There was the possibility of removing my entire AVM, after all the embolisations and treatments I had undergone.

I was lucky enough to meet Professor Lengelé, who took the time to clearly explain to me the extensive operation and its risks. In my case, my face could be paralyzed.

||| I could lose my smile, my trademark... my smile |||
||| or my AVM? |||

That is why I decided to continue the journey with my AVM, because I already know it, and today I am mostly able to control the pain episodes. I prefer to be patient because I believe in miracles and I believe in medicine.

In 2021, I was fortunate to be invited to take part in a clinical trial. The results proved to be incredible.

Today, I have virtually no pain. Research is progressing and the results are very encouraging. I am happy, my life is joyful and that is thanks to my mum, my father -who died in 2022-, my partner and of course my son, who had to put up with all these things, who must have cried without ever telling me.

||| They saw me as a person and we went through |||
||| those difficult times together. |||

I am involved in VASCAPA myself, managing social media. I post news and reply to messages. With another volunteer, we try to share all the information and give the best possible guidance to mums, dads and patients looking for a contact, a name, a word.

		I have decided to invest myself to help others,		
		because it is together and in this way that we		
		will heal.		



Members of the VASCA WG at their Winter Meeting in Brussels, January 2023

Source: VASCERN

Port Wine Stains/ Capillary Malformation and Sturge-Weber Syndrome: Frequently Asked Questions Regarding Laser Treatment

Eulalia Baselga, MD, PhD

1) What is Sturge-Weber Syndrome?

Sturge-Weber syndrome (SWS) is a rare vascular disorder defined by the presence of at least two of the following anomalies: A vascular stain on the face, also called port wine stain (PWS) or capillary malformation; glaucoma (high eye pressure), and increased capillaries in the leptomeninges (which are the innermost layers of tissue that cover the brain and spinal cord).

2) What is the cause of SWS?

SWS is due to a somatic mutation in the gene **GNAQ** that activates its pathway, which plays an important role in the growth of vascular tissues.

A somatic mutation means that the mutation occurs after the fertilisation of the ovum by the spermatozoid, that is, after the zygote is formed. The mutation occurs by chance during the subsequent cell divisions of the embryo. This means that not every cell of the embryo carries the mutation but only a few ones, and the mutation cannot be passed to the descendants.

3) Who is at risk for SWS? Is anyone with a port wine stain on the skin at risk?

Children that are born with a PWS affecting the forehead area are at risk of SWS. (Figure 1)

This is probably because the skin of the face above the eyes (forehead area), the eye and the leptomeninges all derive from the same part in the embryo (the prosencephalon). Therefore, a mutation in the developing prosencephalon will understandably affect the skin of the forehead, the eye and the leptomeninges. The risk of having SWS depends also on the size of the stain. The risk is higher in larger stains or those with involvement of both sides of the face.

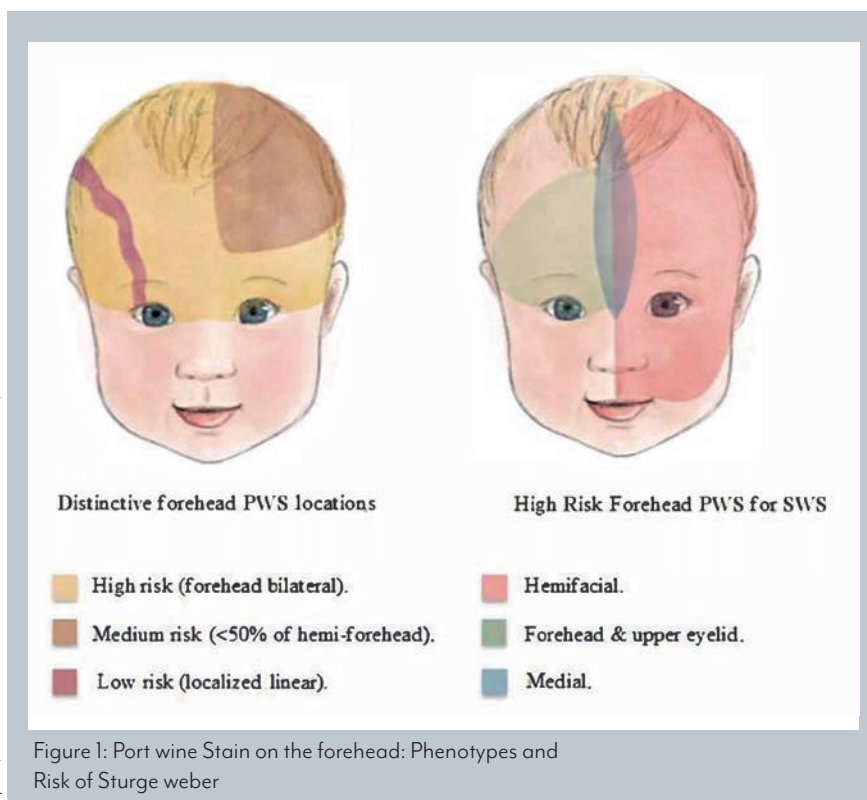
4) What is the recommended work up for children at risk?

Newborns with a capillary malformation/ port wine stain affecting the forehead area should be seen early on by an ophthalmologist with experience in paediatric glaucoma as it may be congenital (meaning that it is present from birth) or may develop later, and therefore long-term follow-up is needed. The leptomeningeal angiomas (increased blood vessels in

the outermost layer of the brain) can be seen on a magnetic resonance imaging (MRI) with contrast. MRI in babies and young children needs sedation as they must be still. There is a high controversy about the need to put an infant under anaesthesia so early for screening and therefore in some centres MRI is deferred until the child is at least one year old. In other centres MRI is performed after feeding and swaddling the infant to induce natural sleep (feed and wrap technique) to avoid sedation. There is also a chance of not being able to see leptomeningeal angiomas when MRI is performed very early on (i.e., in the first 8 weeks of life).

5) How does leptomeningeal angiomas manifest? Is it always symptomatic?

Children with leptomeningeal angiomas may have neurological symptoms such as seizures, usually on the opposite side to the



stain. Seizure activity in children with SWS usually starts in early infancy or during the first year of life. Infants with not well controlled seizure activity with long lasting seizures may have some developmental delay.

Seizures can be treated with antiepileptic drugs and more than one medication may be necessary. If seizures are not well controlled with medication, epilepsy surgery may be an option.

■ **About half of the patients with SWS complain about headaches. Migraine represents the most frequent type of headache. Headaches commonly occur after epileptic seizures.**

Loss of strength or decreased movements (hemiplegia) may occur in some patients on the opposite side of the facial stain. It tends to occur after an episode of seizures. Sometimes a transient hemiplegia (episodes of temporary paralysis) occurs, not following an epileptic attack and sometimes accompanied by migraine-like headaches.

6) How does glaucoma manifest? Can it be treated?

Children with SWS may have glaucoma (high pressure in the eye); if this is not treated it may cause loss of vision. Glaucoma may be present at birth (congenital glaucoma and be recognised by a bigger eye) or develop afterwards with two peak periods: one in infancy and one in later young adulthood. This is why long-term follow-up is needed. Glaucoma can be treated with surgery or eye drops depending on the case.

7) Can the stain be treated? Is it necessary to treat?

The PWS can be treated with a vascular laser, usually a pulsed dye laser. The decision to treat the stain or not is a very personal one. There are several aspects to consider. One must consider that the stain will clear, but will almost never disappear completely and that it will be a long journey, as there will be several treatments involved.

It is important that if the decision is made to proceed with treatment, the right centre with experience in treating infants and children is chosen and that the correct laser is used.

8) How does a laser work?

The laser emits energy in a wavelength that is mainly absorbed by the red colour. Therefore, blood absorbs the energy, transforming it into heat and the capillaries are destroyed without burning the skin.

9) Is the laser painful?

The sensation of a pulsed dye laser is said to be similar to the impact of the snapping of a rubber band against the skin. There is some discomfort associated with the laser, but is momentary and subsides very quickly. In older motivated children it is usually well tolerated with the application of an anaesthetic cream 40 minutes prior to the procedure. Young infants usually cry during the procedure, but the crying does not last more than 10 to 20 seconds after the end of the session when the child returns to the arms of their parents. Saccharose and distracting methods may help to tolerate the procedure. In toddlers, laser treatment is usually performed under sedation or anaesthesia. The anaesthetic risk associated with this type of procedure is very low, because it is not a deep anaesthesia and the procedure is short.

10) How many treatments are needed?

It is difficult to know up front how many laser sessions each lesion will need because it depends on many factors:

- **Location:** PWS on the face usually respond better than those on the arms or legs. Within the face there are also locations that respond better than others: the cheeks, jaw, and moustache area tend to be more resistant than the forehead and temples.
- **Depth of the lesion:** The laser reaches well the blood vessels that are within 1 mm depth. Not all the blood vessels in a given PWS are at the same depth. That is why there are areas that will respond better than others.
- **Skin colour:** Melanin absorbs laser light and prevents it from reaching red blood cells. Light skin types tend to respond better. It is very important not to be tanned on the day of the laser treatment.

In the first session, it is possible that the medical team performs a therapeutic test using different energies and parameters to evaluate the response and choose the parameters to be used in the following sessions. Most improvement is usually observed during the first 4 or 5 sessions. Following on, the improvements tend to be less evident from session to session. On average, between 10 and 15 laser sessions are performed, but this will depend on the individual response of each patient.

11) Would the PWS disappear completely after laser?

■ **Laser treatment can achieve an average clearance of 80% so that the PWS becomes much less noticeable. In very few cases it can achieve complete clearance.**

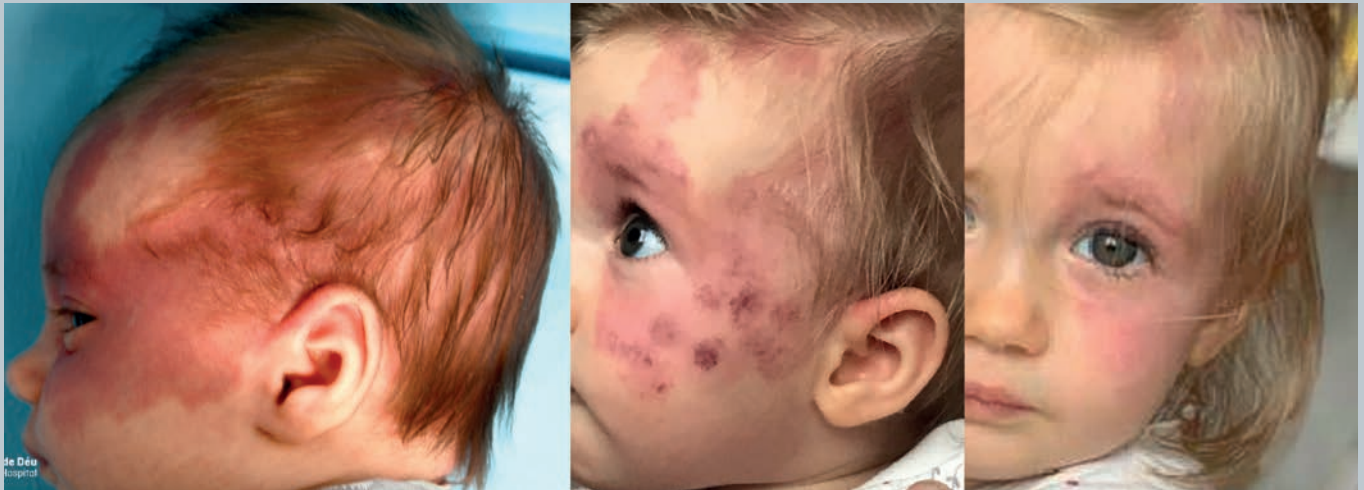

Figure 2: Before and after 3 sessions of PDL. Note the purpura 3 days after a laser treatment.

Source: Patients pictures database; Hospital San Joan de Deu, Children's Hospital, Barcelona, Spain

Sometimes, over the years, capillary malformations can gain some colour, so some maintenance treatment may be necessary once a year or every two years throughout life.

12) When should the laser treatment be started?

The sooner the treatment is started, the better the response. Infant skin is thinner, has less melanin, and contains a higher proportion of red blood cells maximising the absorption of laser light. PWS tend to thicken with time which makes laser penetration more difficult.

13) How often can the sessions be done? Why?

Ideally, every 6 weeks. After laser treatment, the purpura resulting from the laser treatment takes time to resolve (10 to 14 days). On the other hand, 6 weeks gives the skin time to fully recover.

Clinical studies have shown that performing laser treatment every two weeks does not improve results compared to sessions every six weeks.

14) Is the laser safe even if the child has glaucoma or seizures?

Laser does not worsen glaucoma or trigger seizures. The eye should be protected with a special shield when a laser is used around the eyes. The eye shield can be easily placed when the child is asleep or with the use of eye anaesthetic drops when the child is awake.

15) What should be expected after a laser treatment. Is there a particular skin care recommendation after laser treatment?

Immediately after the laser treatment, the stain will become darker and violaceous (Figure 2). There should be no open wounds or crusts. This purpura colour will subside in 4-10 days, after which you will be able to see the clearing. In principle, a child can return to normal activities and school right after laser treatment. However, it is recommended to avoid exposure to the sun and to avoid scratching the skin area.



Eulalia Baselga, MD, PhD

Source: Eulalia Baselga

Eulalia Baselga, MD, PhD

Head, Department of Dermatology
Hospital Sant Joan de Deu,
Children's Hospital Barcelona
Passeig Sant Joan de Déu 2
08950 Esplugues de Llobregat (Spain)
HCP VASCERN, Vasca

○ www.sjdhospitalbarcelona.org
○ Eulalia.baselga@sjd.es

Please scan



TESTIMONIAL

Tessa has Sturge-Weber Syndrome

Brenda Kluijver (HEVAS)

Living her way, being completely herself, trusting her path: that is the motto of Tessa Schiethart (29). She was born with Sturge-Weber syndrome, resulting in a large port wine stain on her face and blindness in one eye. Her other eye could potentially go blind in the future.

Immediately at birth, it was clear that something was wrong. “The port wine stain on my face was very noticeable right away. However, the obstetrician said it might go away, and otherwise my parents should just go to the family doctor”, she recalls. “So, for a while they thought it could be a temporary discoloration. But soon my parents realised that the birthmark was there to stay. Fortunately, the GP knew a lot about port wine stains, and the complications that often accompany them. So soon, as a baby, I was in an MRI scanner, looking for underlying problems. However, there didn't seem to be any”.

Vision Problems

But when Tessa went to school as a little girl and could not read the blackboard, it turned out there was more to it.

“The optician discovered that I couldn't see anything at all with my right eye. I was then referred to the ophthalmologist, where it was eventually discovered that my eyes were also affected by Sturge-Weber. For a long time, we wondered whether I was born with this, or whether the vision problem arose later. And why it hadn't been discovered earlier,” says Tessa. “We never found out if it came at birth, or that my sight lessened in my early years”.

No Negative Experiences

The fact that she was raised in a close family in the middle of Amsterdam, Tessa says, helped her learn to live with her condition. “We were emotionally open, nothing had to be hidden. If people asked my mother on the street what I had, I could tell them myself if I felt like it. If I did not feel like it, then my mother would tell them, in a calm and tactful but clear way to the stranger on the street. So, there was never any talking over my head, which was very good.”

“As a young child then, I was very aware of my face and how people reacted to it but had few negative experiences with it.”

Many Hospital Visits

In her young childhood, Tessa was in and out of many hospitals. This left its mark internally and externally.

“In the 1990s, it was normal to give children with a visible port wine stain laser treatment. This would lighten the colour and make the stain less noticeable. When I was two, they accidentally used the wrong laser. It went completely wrong. My port wine stain got burnt. It left me with scar tissue above my eyes and next to my nostrils,” says Tessa. “It has been a long journey to overcome this, from personal injury to trauma for my parents and myself.”

Healing

Around the age of seven, Tessa regularly underwent medical treatments in the hospital, and was very ill.



Tessa Schiethart

Source: Bruno Rezende | Bruno Click Photography

“All that time in hospitals had an impact on my mental health. Trauma stores itself in your body, and certain memories made me suddenly panic completely.”

“Because of a smell, or the memory of the cold I always felt in the hospital. I avoided stress for a long time, because stress felt very unsafe in my body. I knew that feeling all too well. I had to work on that consciously, recovery from the hospital treatments was a slow and gentle healing process.”

Moments of Happiness

Yet there were also 'happy moments' during that period full of treatments, Tessa thinks. “When I was thirteen, I underwent eye surgery to prevent my left eye from going completely blind as well. It was a very risky operation, but by doing nothing I already knew the outcome – and the operation succeeded!”, Tessa says happily. “And when I was 17, I got laser treatment with a 50% chance of success; also successful!”

“Those moments were very decisive for me. Looking at the positive side of things is very important to me.”

Studying

During that time, Tessa completed high school, which she always enjoyed going to. “I loved learning and reading, was never bullied and had a wolf pack of girlfriends around me. I really cherished that. After my exams, I wanted to see the world for as long as I could.” And so Tessa hit the road with her backpack. She lived in San Francisco for a while and travelled through Indonesia and Australia. “I had become so enthusiastic about Southeast Asia that on my return I started studying Southeast Asia studies at Leiden University and immersed myself in yoga and spirituality. Later, I studied anthropology.”

Acceptance

Despite the enjoyable study period, Tessa still had a fear that employers would not hire her because of her port wine stain and vision impairment.

“That seemed so painful to me, that despite your skills and intellect you would stumble upon something so superficial as being rejected because of your looks. Staying true to myself, being my authentic self, living my way and on my terms helped me through that, and it still helps me. It's not easy, but if you choose to walk your own path, it unfolds as it should,” says Tessa. “The port wine stain is part of me, I have accepted that.”

Camouflage

The moments in her adolescence when she wanted to camouflage her port wine stain contributed to that acceptance, according to Tessa. “I always wondered how people related to my appearance. I discovered how I felt about it myself when I tried to camouflage my birthmark with make-up. It was very intense when I saw myself in the mirror; I really didn't dare walk down the street like that. It upset me how I looked; the second attempt also evoked those feelings.

I was so conscious of my face with that make-up on, it didn't feel like my body either. It didn't fit me. So, then I decided: that port wine stain will always stay, this is me.”

Book Written

Meanwhile, Tessa has set up her own coaching practice, where she helps women with physical differences to embrace themselves again. She also wrote the book “**Zien en gezien worden**” (“Seeing and being seen”), which was recently published in Dutch and will likely be translated to English in 2023. It is for sale through (online) bookstores. Her book tells the story of her condition and the way of living with it. “That book is a dream come true. When my sight deteriorated again two years ago, I had to realise my dream. Writing a book while I could still see proved to be a healing process. I enjoy my sight unconditionally; I choose to trust what is, rather than distrust what is to come. That gives me strength.”

Future

That her sight may disappear completely in the future is a dreadful prospect for Tessa, but one she has been able to come to terms with.

“I am ready for whatever happens to my sight. No one knows what their future looks like, and the future is more loaded when you are ill. I believe in a healthy and integrated relationship with your body despite any condition or illness.”

Sturge-Weber syndrome

Sturge-Weber syndrome is a congenital disorder of the blood vessels. Usually, children have a port wine stain on their face and increased eye pressure or other problems with eyesight. Sometimes epilepsy occurs, or limb disorders.

TESTIMONIAL

Anouk is Living with PTEN Hamartoma Tumour Syndrome (Cowden Syndrome)

Diana de Veld

Despite all kinds of health problems, including vascular malformations, Anouk Greven enjoys life. She shared her impressive story with HEVAS Magazine. Here you can find a summary.

Netherlands-based Anouk (31) lives with her parents in Limburg. She has completed a college degree in communication & multimedia design and is now looking to become an online marketer. She says: "I have a wonderful boyfriend, Javéry, and a lovely sister, Femke; both are always there for me".

Difficulty somersaulting

When Anouk was eight years old, her health problems began.

Her mother tells, "It started with mild epileptic seizures. She had trouble somersaulting. She could not bring her chin to her chest properly; it hurt too much. A very small lump was found near her neck. The lump had a stalk; there appeared to be a tumour in the chest. We were immediately referred to the Amsterdam University Hospital AMC".

PTEN mutation

'The tumour turned out to be malignant at its core, but not around it,' recalls Anouk's mother.

After additional tests, it was found that Anouk had Cowden syndrome, or a PTEN mutation (see box on next page). During the same period, Anouk's father started having bowel problems and extreme fatigue. "Because Anouk's gene defect had been identified, we discovered that he too has a PTEN mutation". says her mother. So, Anouk inherited the disease from her father.

Fifty times under the knife

Anouk faced further health problems. "She had a vascular malformation in her shoulder", her mother recounts, but they



Anouk Greven

Source: Anouk Greven

failed at removing it. She had a growth behind her eye, the thyroid gland was malignant, there were lots of benign tumours in the breasts. There was a benign tumour in the brain (meningioma) and three years ago an aneurysm led to a brain haemorrhage followed by meningitis.

By now, Anouk has been under the knife 50 times. From this intense period, Anouk has recovered well.

"With many thanks to the rehabilitation centre Adelante in Hoensbroek."

Switching hospitals

Until she was eighteen, Anouk attended the Emma Children's Hospital within the AMC (now Amsterdam UMC), after which

she had to move. “I switched to Radboudumc and there things are fantastic. I was eligible for the drug sirolimus. The doctors took my pain seriously and dealt with it”.

Netflixing after embolisation

Currently, Anouk is doing well, apart from extreme fatigue. Anouk is still taking medication for nerve pain in her shoulder. “Twice a year the arteriovenous malformation in my shoulder is embolized to prevent further growth. I will go Netflixing then to recover, unfortunately it cannot be completely removed”.

Positive attitude


What is remarkable is Anouk's positivity, despite her health problems. She also experiences a lot of support from her parents and from her sister.

“When I'm at a loss for words, she nudges me and says: come on, keep going! We also undertake a lot together.”

PTEN mutation

A mutation in the PTEN gene is very rare: about 1 in 200,000 people have PTEN hamartoma tumour syndrome. This congenital syndrome involves a variety of symptoms, but the extent to which people get these symptoms varies greatly from person to person. Skin abnormalities and hamartomas (a certain type of benign tumour) are common. The risk of all kinds of cancers is increased. Vascular malformations are seen in a large number of PTEN patients. Autism and/or cognitive problems are also part of the spectrum of the PTEN hamartoma tumour syndrome. Although there are a variety of treatments for the symptoms, the mutation itself cannot be cured.

VASCERN VASCA-WG



VASCA ePAG



www.vascern.eu

VASCA Working group Experts and Patient advocates

Congresses and Meetings on Vascular Anomalies

CLINICAL CONGRESSES

ISSVA World congress

Congress of the International Society for the Study of Vascular Anomalies, about the latest developments in vascular anomalies: Presents advances in the understanding of the causes, clinical trials and management of vascular anomalies.

Frequency: every two years

Last edition: 10-13 May 2022 in Vancouver, Canada (hybrid)

Next edition: 7-10 May 2024 in Madrid, Spain (hybrid)

www.issva.org



ISSVA Debates & Updates meeting

Meeting organised by the International Society for the Study of Vascular Anomalies, with lively panel discussions, case reviews and interaction with participants.

Frequency: every two years

Launched in 2021 (virtual)

Last edition: 19-21 April 2023, Boston USA.

www.issva.org/2023



EADV Congress

Congress of the European Academy of Dermatology and Venereology, where the latest research and cutting-edge scientific developments are presented. While it focuses on dermatology, vascular anomalies are discussed among many other topics.

Frequency: every year

Last edition: 11-14 October 2023, Berlin, Germany

Next edition: 25-28 September 2024, Amsterdam, The Netherlands

<https://eadv.org>



EADV Symposium

Symposium of the European Academy of Dermatology and Venereology, about the latest on Psoriasis and Non-melanoma skin cancer, as well as Dermoscopy, Acne, Paediatric dermatology, and more.

Frequency: every year

Last edition: 18-20 May 2023, Sevilla, Spain

Next edition: 16-18 May 2024, St Julian's, Malta

<https://eadvsymposium2023.org>



CONGRESSES ON SPECIFIC (GROUPS OF) DISEASES

World AVM Congress

Presentations on the latest data, concepts, and breakthroughs in our ever-expanding understanding of the management of CNS (central nervous system) AVMs. This edition of the congress included specialists of peripheral AVMs.

Last edition: 24-25 April 2022, Val d'Isère, France

ABC-WIN seminar

Last edition: January 14-19, 2024, Val d'Isère, France

www.abcwin-seminar.com



ISL World Congress of Lymphology

This Congress, organised by the International Society of Lymphology, is about the latest advances in lymphology and brings together the International Lymphology Community: scientists, physicians, surgeons, therapists, researchers, industry and healthcare providers. A special section will be dedicated to patients and their associations.

Last edition: 11-15 September 2023, Genova, Italy

www.isl2023lymphology.com



European Congress of Lymphology

Congress on new scientific researches in the lymphological field, organised by the European Society of Lymphology (ESL)

Frequency: every two years

Last edition: 16-18 June 2022, Assisi, Italy

Next edition: 30 May - 1 June 2024, Istanbul, Turkey

<https://esl2024.org>



CONGRESSES ON GENETICS

ICHG

International Congress of Human Genetics. This congress presents an opportunity to showcase Genetics/Genomics across the world, bringing together international experts, as well as young postgraduates addressing challenges in human health and highlighting how genomic technologies are being harnessed to address such challenges.

Frequency: every five years

Last edition: 22-26 February 2023, Cape Town, South Africa

www.ichg2023.com



European Human Genetics Conference

Conference of the European Society of Human Genetics (ESHG). Scientific and professional event in human genetics which brings together European and international geneticists.

Frequency: every year

Last edition: 10-13 June 2023, Glasgow, Scotland, UK

Next edition: 1-4 June 2024, Berlin, Germany

www.eshg.org



ASHG annual meeting

5-day conference of the American Society of Human Genetics (ASHG).

Forum for the presentation and discussion of cutting-edge science in all areas of human genetics.

Frequency: every year

Last edition: 1-5 November 2023, Washington DC

Next edition: 5-9 November 2024, Denver, Colorado

www.ashg.org/meetings/2023meeting



CONGRESSES ON FUNDAMENTAL AND TRANSLATIONAL RESEARCH

GRC Lymphatics

Gordon Research Conference on lymphatics, which brings together international scientists and clinicians working across all aspects of lymphatic vessel biology to discuss the latest advances in this field. The meeting features cutting-edge science in developmental biology, genetics, physiology, immunology, metabolism, mechanobiology, systems biology, mathematical modelling and human disease. Held in conjunction with the "Lymphatics" Gordon Research Seminar (GRS).

Frequency: every two years

Last edition: 30 Oct - 4 Nov 2022, Lucca, Italy

Next edition: 3 - 8 March 2024, California, USA

www.GRC.org



GRC Endothelial Cell Phenotypes in Health and Disease

Gordon Research Conference with a focus on the endothelial cell compartment of the vasculature, and the inherent heterogeneity within this compartment, because it is crucial for blood and lymphatic vessel development, function and regeneration. Held in conjunction with the "Endothelial Cell Phenotypes in Health and Disease" Gordon Research Seminar (GRS).

Frequency: every two years

Last edition: 26 June - 1 July 2022

Next edition: 29 June - 5 July 2024,

Castelldefels, Spain

www.GRC.org



International Vascular Biology Meeting (IVBM)

Meeting about diverse research topics in vascular biology from basic to translational level.

Frequency: every two years

Last edition: 13-17 Oct 2022, Oakland, USA

Next edition: 2-5 July 2024, Amsterdam, The Netherlands

www.IVBM2024.org



Kloster Seeon Meeting 'Angiogenesis'

Conference about molecular mechanisms and functional interactions in vascular development and diseases.

Frequency: every two years

Last edition: 17-20 September 2022,

Kloster Seeon, Germany

www.vwfb.de



Lymphatic Forum

Event that brings together researchers from around the world to present and discuss studies of lymphatics in health and disease.

Next edition: 13 -17 June 2023, Banff, Alberta, Canada

Frequency: every two years

https://lymphaticforum.org



International Conference on Vascular Anomalies (VAC2023)

An event that brings together researchers and clinicians from around the world to discuss vascular anomalies, with the intent to translate basic research into new therapies.


First edition VAC2023:

31st January to 3rd February 2023, Brussels, Belgium

Next edition VAC2025:

11-14 February 2025, Berlin, Germany

<https://vacure-conference.net/>



The organising V.A. Cure network

Source: V.A. Cure network



We have used this service for this magazine and say thank you.

Free for commercial usage

All generated QR Codes are 100% free and can be used for whatever you want. This includes all commercial purposes.

www.qrcode-monkey.com



Source: www.qrcode-monkey.com

NATIONAL CONGRESSES AND MEETINGS**Austria**

Tagung der Österreichischen Arbeitsgruppe für Interdisziplinäre Behandlung Vaskulärer Anomalien (AIVA)

Next edition: 8/9 March 2024

in St. Wolfgang / Salzkammergut, Austria

www.aiva.at/

**France**

FAVA-Multi, the french health network for rare vascular diseases with multi-system involvement, which includes superficial vascular anomalies.

Next edition: June 14, 2024

<https://favamulti.fr/>

**Germany**

Deutsche Interdisziplinäre Gesellschaft für Gefäßanomalien e.V. (DIGGEFA)

Last edition: 13/14 October 2023 in

Regensburg, Germany

Next edition: Fall 2024

www.diggefa.de

**Italy**

Italian Society for the Study of Vascular Anomalies (SISAV)

Last edition: 12-13 September 2023 in Genova, Italy

Next edition: February 2024 in Milan, Italy

<https://www.sisav.eu/>

**The Netherlands**

Dutch network for expertise centres for vascular anomalies (biennial) conference on vascular anomalies for other medical specialists

Last edition: 7 November 2023 in the Netherlands

<https://aangeborenyaatafwijkingen-expertise.net>

**Norway**

NSVA Nordic Society for Vascular Anomalies

Last edition: 26-27 September 2022 in Oslo, Norway

Next edition: 16-17 September 2024 in Helsinki, Finland

www.nsva.no

**Spain**

SEAV Sociedad Española de Anomalías Vasculares

Last edition: 20-21 October 2023 in Sevilla, Spain

Next edition: October 2024 in Barcelona, Spain

<https://ww2.seav.org/>

**Portugal**

congresso Nacional de Anomalias Vasculares /National Meeting of Vascular Anomalies

Last edition: 24 March 2023 in Porto, Portugal

<https://www.spp.pt/eventos/default.asp?ida=12542>



Highlights from ISSVA 2022

Bas Verhoeven, MD

The ISSVA Congress 2022 took place in Vancouver. In addition to several online participants, there was a large delegation of representatives from centres of expertise, young doctors, researchers and some patient associations.

Surgery and Interventional Radiology

Surgery can still have an additional role after interventional radiology or after/during drug therapy. As more drug therapies become available and their usage increases, the use of intervention radiology alone has also decreased.

Medication

Medical treatment options for symptomatic patients with vascular malformations and tumours are increasing and as a result we are seeing a more important role for specialists such as haematologists, vascular physicians and paediatricians in centres of expertise. Treatment with atenolol, propranolol, fraxiparin (LWMH), DOACs, sirolimus, alpelisib, trametinib, thalidomide, and other drugs can offer relief to patients who do not benefit sufficiently (or not at all) from conservative treatments or invasive techniques such as interventional radio-

logy and surgery. Drug therapy can sometimes be chosen as the only treatment, depending of course on the side effects. Whether based on genetic mutation analysis and known pathological "pathways", or started empirically because there are no alternative treatments to offer yet the suffering of the patient is too great, drug therapies can give hope and opportunities for reducing symptoms and increasing quality of life for patients. Current drugs can also be used peri-procedural so that invasive treatments lead to fewer complications (e.g., peri- and post-operative bleeding). "Neo-adjuvant" deployment of medication can still make surgery of initially inoperable defects possible by "downsizing" the lesion.

||| All in all, according to Francine Blei, new drugs are on the way and hope remains to ||| find the "golden bullet".

Infantile Haemangiomas (IH)

Since 2008, propranolol has been the main treatment for IH. There is a lot of experience with atenolol in The Netherlands. A Dutch study found no differences in efficacy or long-term (side-)effects between children treated with propranolol and those treated with atenolol.



VASCA WG doctors and ePAG representatives

Source: VASCERN

Mutations and the Role of Genetic Diagnostics

Many studies performed and presented at ISSVA 2022 focused on genetics. Besides clinical presentation, symptoms, localisation(s) and the presence or absence of haematological peculiarities, the outcome of DNA mutation analysis is indispensable in understanding pathophysiology and treatment options. Whether or not the patient is dealing with for example ACVRL1, (K)RAS, MAPK, PIK3CA, TIE2/TEK, BRAF, RASA1, MTOR or AKT1 mutation, inhibiting the (associated) "pathways" gives new opportunities but also brings new risks and questions. To what extent is inhibiting (or long-term inhibiting) safe for the patient and what dosage is right? What is the role of double mutations? Do we treat genotype, phenotype or the whole patient?

Cell-free DNA

Obtaining tissue is sometimes difficult (not safely accessible, painful procedure, scar, bleeding, infection, complications, contraindicated). There are increasing initiatives to extract DNA from circulating blood (and cysts). A striking finding is that DNA of the lesion may be easier to obtain in blood after embolisation. This is a promising technique that will be developed further in the near future.

On GNAQ-209-positive Port Wine Stains


Two different GNAQ mutations give a different picture of port wine stains or Sturge Weber syndrome (SWS). Port wine stains with the GNAQ-209 variant have a stronger tendency to ulcerate.

On GNAI1_SWS

In addition to a GNAQ mutation, the GNAI1 mutation can also cause port wine stains and present a picture similar to Sturge Weber syndrome. For the GNAI1 mutation, the SWS picture appears to be milder than for the GNAQ mutation, three patients were aggregated by the centres of expertise from Caen, Brussels and Nijmegen and the findings were presented as a co-production.

On PROMs, HRQOL, OVAMA and SDM

Research has to be done into the best ways to contribute to quality of life for patients with vascular anomalies. In this era of macro-economic limited financial resources and capacity we also have to know what the most cost-effective diagnostics and treatment is. These topics were addressed in various presentations and discussions. A number of projects such as PROMIS and PROVAM focus specifically on improving the mea-



surement of quality of life. Pain has a significant negative impact. Many invasive treatments cause an acute period of additional pain on top of the often chronically present pain symptoms. This aspect is taken into account when choosing the treatment pathway together with the patient ("shared decision making" or SDM). The process of SDM can be supported by multimedia educational materials as presented and evaluated at the congress ("PEMAT-A/V survey").

Classification

The insights around "our" disease based on genetic pathophysiology are rapidly changing, resulting in lively discussions around necessary adjustments to the 2018 ISSVA classification, to be presented at ISSVA 2024 in Madrid.




Bas Verhoeven, MD

Paediatric Surgeon
Radboud university medical centre /
Amalia paediatric hospital

○ Bas.Verhoeven@radboudumc.nl

○ www.radboudumc.nl

On behalf of: Carine van der Vleuten, Edith Klappe, Veroniek Harbers, Horst Daniels, Leo Schultze Kool



The Research Work Performed on Vascular Anomalies at the Laboratory of Humans Genetics of the de Duve Institute

Prof. Miikka Vikkula, MD, PhD, Francisca Voermans, drs. ir.

In the previous VASCA magazine you could read about the importance of genetic research in the development of new treatments for vascular anomalies. We now want to give you an insight into how genetic research is performed in the laboratory of Prof. Miikka Vikkula.

Some 25 years ago, Miikka Vikkula started his lab at the de Duve Institute, next to Saint-Luc hospital in Brussels, Belgium, to do genetic research on vascular anomalies. His group has since discovered multiple genetic mutations that cause various types of these rare diseases. But his ultimate goal has not been reached yet.

“There are still patients who do not know what causes their disease. We want to identify the genetic causes for all patients”, he says.

Genetic analysis has been revolutionised in the last decades. Thanks to technical advances, both the time needed and the costs have fallen drastically. One of the consequences is that genetic analyses are now commonly performed in the hospital. “Today, when a patient with a vascular disease comes to the hospital, the clinician will do a genetic test. In many cases this will lead to a diagnosis. But not always. If the result is negative, the clinician can send the samples to us”, says Miikka Vikkula.

Due to the close collaboration with the Centre of Vascular Anomalies of Saint-Luc Hospital, his lab, called GEHU (Human Genetics), has a unique bridging position between clinical and fundamental research.

The lab collects blood and tissue samples of all types of vascular anomalies. These samples are the starting point of the research in the lab. They are analysed and stored at cryogenic temperatures. Frequently samples are

analysed again, many years later, because there is new technology or new knowledge.

The research is laborious work that takes many years, during which multiple steps are taken.

1. Genetic Research

The genetic research in the lab is different from the genetic analyses in the hospital. “The hospital analyses for two or three specific genes that are known to be mutated in vascular



DNA sequencing

Source: Institute de Duve

anomalies. We analyse the whole exome, which is the part of the genome that is used to form proteins (“codes” for proteins). Though this is only 1 percent of the total genome, the exome still consists of around 80 million base pairs.” For the analysis, first the DNA is extracted out of the blood or tissue samples. The DNA is then sent to a specialised company for the genetic analysis, called Whole Exome Sequencing (WES). “The resulting DNA sequence is compared to a human reference sequence.

The outcome is a file with all genetic differences (variants). Normally there are around 60,000.” The researcher now tries to identify which of these 60,000 variants is causing the disease.

The GEHU lab has developed a software program, called Highlander, to filter the variants. “The filtering is based on negative selection: we filter out variants that are known from international databases or from our own databases and do not cause the disease. We also delete variants that are found in all samples and thus are due to technical issues. This reduces the number of variants to a few thousand.”

To further narrow down the number of variants, the researcher searches for “stop codons” in the variants. A stop codon is a short DNA sequence that tells the protein transcription machinery to stop. Normally this means that the protein is completed, but if the stop codon is generated due to a mutation, this may lead to a shorter or absent protein.

A stop codon in a variant may indicate a disease causing mutation. These stop codons are quite easy to identify. Most variants however are substitutions, which means that, in the produced protein, one amino acid is swapped for another. To find out which of these substitutions may cause the disease, the researcher compares similar patients.

“Patients with similar symptoms often have mutations in the same gene, though not necessarily the exact same variant. If we have three patients with mutations in the same gene, we have a good chance to find the cause of the disease in this gene. For the rarer cases, it gets very complicated.”

The researchers have another tool to find out which variants may cause the disease: mathematics. They use 20 algorithms to predict whether a substitution alters the function of a protein. If many of the 20 algorithms predict a change of function, it may be a substitution that causes a disease. If none or only a few predict a change of function, it probably has no effect.

2. In Vitro Research

The genetic research results -if successful- in a few candidate mutations that are likely to cause the disease. The next step is to verify if they indeed have the capacity to harm the cell function. To investigate this the researchers do in vitro experiments, which means experiments with cells that are cultured in the lab. They create a gene with the mutation and insert it into a carrier DNA-molecule, called a vector or plasmid. This vector carrying the mutated gene, is introduced into a cell, after which this cell is multiplied by culturing in the lab.

The mechanisms in the cells start to express the mutated gene and the cell thus produces the mutated protein. “We can now see if the cell shows abnormalities: changes in size, in adhesion to plastic, in the membrane. We often do Western Blots, a technique to determine the size of the proteins. And we can do analyses of all molecules of a certain type in what we call “omics”, like metabolomics, where we analyse all metabolites, or proteomics where we analyse all proteins.” From these experiments, the researcher learns which changes the mutation induces in a cell, and he can estimate whether they could lead to a malformation.

The results may also give an indication about how these changes can be stopped. If for example a certain pathway is found to be involved, an inhibitor of this pathway might be used for treatment.

3. In Vivo Research

The in vitro experiments will not tell if the mutation will really have an effect in a human body and what the consequences will be.

The next step in the research is therefore animal (or in vivo) research to determine how the mutation affects a whole living organism. In vivo research into the vascular system is done with mouse or zebrafish models. A model is created by inserting the mutated gene into the animal. This gene is silenced, meaning it will not be expressed. By crossing the model with another mouse (or zebrafish), the gene can be expressed in the tissue that the researcher chooses.

“We can activate it only in the vascular system, and not in the brain or liver. Or even more precise: only in the lymphatic system. We can then see if the mutation is able to create a malformation. It is also possible to vary the time point of activation, so we can simulate the point of development. From such experiments we know that if a mutation becomes active in a late stage, it does not induce the development of a malformation. And we learned that if the mutation is inactivated

in an early stage, the malformation disappears and the tissue can normalise again. Apparently, the cell has some kind of memory.”

||| If a mutation proves to be able to induce a malformation in the vascular system of the animal model (and because it is present in patients), the researcher can say that this mutation is the cause of the disease.

The in vivo models may further be used to screen a number of active molecules that might be candidates for a therapy. For example molecules are tested that have already been approved by the American FDA or that are used in humans for another disease (repurposing).

4. Clinical Trials

If a molecule proves effective for the treatment of a malformation in animal models, the research is continued in the hospital.


In clinical trials, following well defined procedures, the molecule is tested in a few patients to investigate the effectiveness of the treatment, as well as the possible side-effects.

||| This makes the circle complete: the research that started from patient samples comes back to the patients. “The participation of patients is very important in the development of a new treatment”, concludes Miikka Vikkula.

Who Works in the Lab?

The workforce in the laboratory is composed of people in different stages of their career.

The youngest researchers are graduate students who do an internship in the lab during the second year of their master (for example in biochemistry, molecular biology, bioinformatics). After graduation they can continue in research as a PhD or Doctoral student. They will work on their



Preparing samples

Source: Institute de Duve

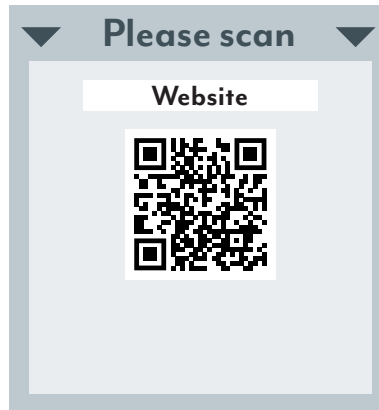
own project, usually for four years, after which they write a thesis and get a PhD degree. Most PhD students have a degree in a field mentioned above, but also graduates from medical school with an interest in research can choose for a PhD. For those who wish to continue a career in academic research, the next step is to become a Postdoc. A postdoc position is often for two years, but can be longer, during which the researcher further develops his or her research skills. Further on, the lab has senior researchers with a position as associate

professor or assistant professor. Some senior researchers combine research with working in the hospital. A full professor, also called Principal Investigator (PI) heads the lab. He or she sets the direction of the research and is responsible for the ins and out of the lab. Last, but not least, there are technicians, who are very skillful in performing experiments. Though it is possible for a researcher to stay in one institution during his career, many go to other countries for parts of their training. A lab's crew is therefore very dynamic and international.

Source: Jan Van De Vel - RED22 / Institut de Duve



Prof. Miikka Vikkula, MD, PhD



Prof. Miikka Vikkula, MD, PhD

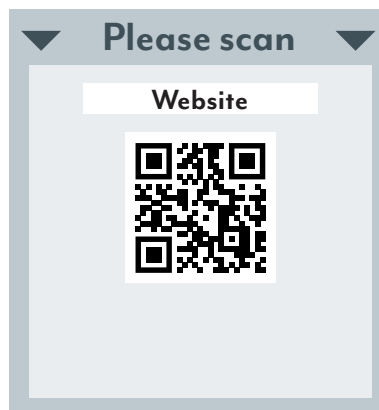
Laboratory of Human Genetics
de Duve Institute
Avenue Hippocrate 74
Woluwe-Saint-Lambert
1200 Brussels
Belgium

- miikka.vikkula@uclouvain.be
- www.deduveinstitute.be

Source: Jan Van De Vel - RED22 / Institut de Duve



Francisca Voermans, drs. ir.



Francisca Voermans, drs. ir.

Institut de Duve
Génétique cellulaire
GECE
Avenue Hippocrate 74/B1.74.04,
1200 Woluwe-Saint-Lambert
Belgium

- francisca.voermans@uclouvain.be
- <https://uclouvain.be>

kreativ & sozial
Agentur für Medien-Design

Creative advertising for social causes.
Professional, personal and fair.

You serve people, I present to the outside world how well you do it.
From concept to layout to implementation. Vast experience in magazines.
Across national borders. Communication in English (only e-mail) or in German.



www.creative-and-social.eu

Source: Kathrin Sachse

Sirolimus in Slow-flow Vascular Anomalies: a Current Overview

Emmanuel Seront, MD, PhD, An Van Damme, MD, PhD, Miikka Vikkula, MD, PhD, Laurence Boon, MD, PhD

Vascular malformations result from early defects in vascular development and are classified as slow flow (venous, capillary, lymphatic) or fast flow (arteriovenous malformations) (1-3). Venous malformations (VMs), the most prevalent, are usually present at birth, appearing as unifocal, blue-coloured, soft and compressible lesions. As they progress and expand over time, they cause a variety of symptoms (such as pain, deformity, restricted function and bleeding) and can lead to potentially life-threatening complications due to their impact on vital structures and associated coagulation issues (1-3). Treatment options include surgical resection and sclerotherapy. However, these procedures are rarely curative or are sometimes not feasible in patients with extensive and infiltrating lesions (4-6).

Venous malformations at the molecular level

Venous vessels are composed of a border of endothelial cells covered by pericytes, allowing vessel stability and maturation.

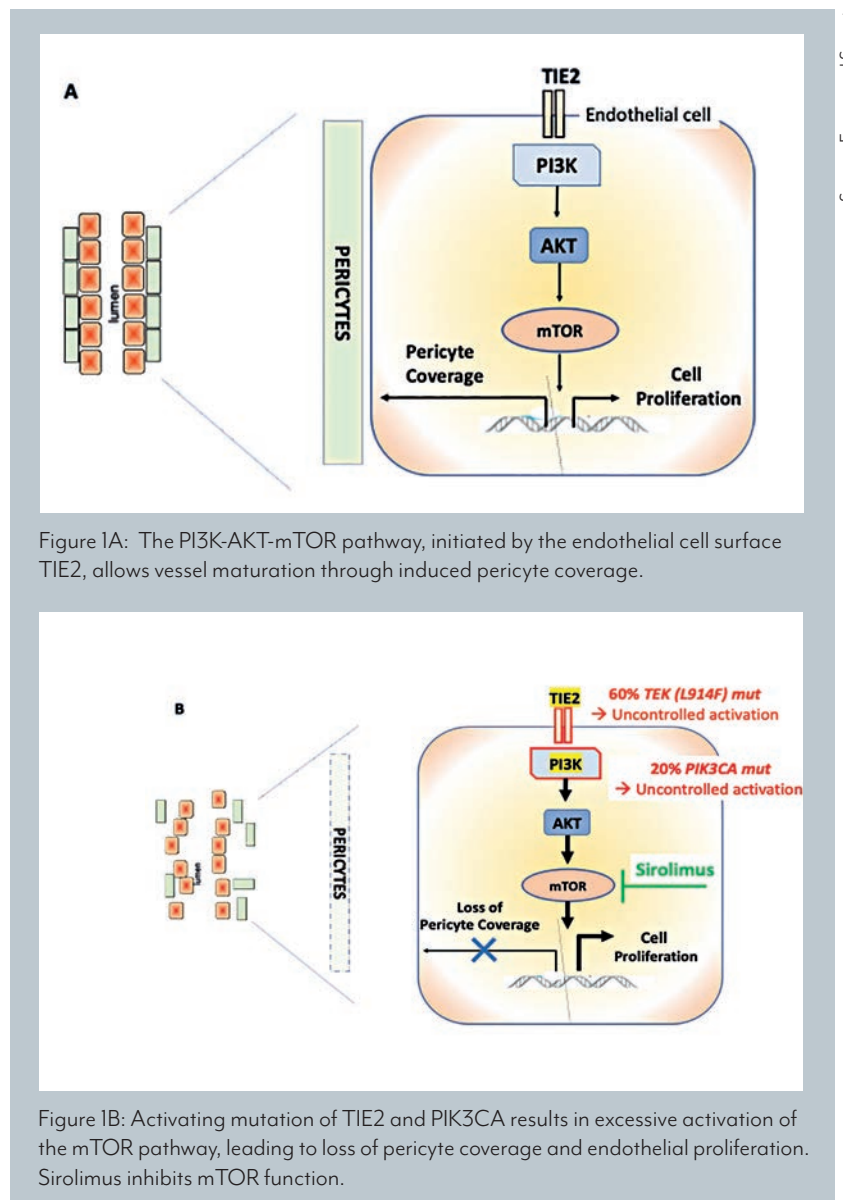
This balance is orchestrated by the TIE2 receptor located on the endothelial surface, initiating the activation of the phosphoinositol 3-kinase (PI3K) - protein kinase B (AKT) - mammalian target of rapamycin (mTOR) cascade (7-16). Up to 60% of VMs have an activating mutation in the TEK gene encoding the TIE2 receptor and 20% have an activating mutation in PIK3CA, the gene encoding PI3K. These mutations result in an excessive and uncontrolled activation of AKT and mTOR, leading to anarchic proliferation of endothelial cells and excessive detachment of pericyte coverage. These mutations are in most cases somatic and non-inherited, meaning that they occur at an isolated location during the early development of the vasculature and that the defect is not transmitted to the next generation (Figure 1A and B) (10-16).

Sirolimus also referred to as rapamycin, functions by inhibiting the activity of mTOR and has applications in various medical conditions, including cancer treatment and organ transplan-

tation. Its potential in addressing vascular malformations was initially explored through mouse models. These models were developed by injecting mutated endothelial cells subcutaneously, leading to the formation of venous malformations in mice. Preclinical studies revealed that sirolimus effectively inhibits the progression of venous malformations by reinducing vessel maturation (14, 15).

Sirolimus: results from VASE trial

For a decade, different phase II trials, retrospective cases and case series analyses have suggested a promising efficacy of sirolimus. However, due to inherent limitations in terms of patient



Source: Emmanuel Seront

numbers, patient population and design, they were unable to confirm sirolimus as a new standard treatment in vascular malformations (14,16,18-20).

The phase III VASE trial is a multicentre study evaluating the efficacy and safety of sirolimus in patients with complex slow-flow vascular malformations that are refractory to standard treatment (EudraCT 2015-001703-32).

All participants started on a standard dose of sirolimus: 2mg for adults and 0.8mg twice daily for children. Sirolimus doses were adjusted based on individual symptoms, tolerability, and serum sirolimus concentrations. Notably, sirolimus was given for two years with the option of reintroduction if symptoms recurred.

In November 2023, we published the results of the first 132 patients (31 children and 101 adults) with at least 12 months of follow-up after starting rapamycin, including 76 patients with VMs.

Sirolimus confirmed its impressive efficacy; with 85% of patients showing significant improvement in pain, functional limitation, decrease in pain, oozing and/or bleeding (Figure 2).

Beyond demonstrating sirolimus's high efficacy rate, this trial provided valuable insights into response profiles.

- Sirolimus may have a rapid effect, with 70% of patients reporting improvement within the first month of treatment. However, up to 20% of patients may experience a temporary worsening of symptoms in the first few months before achieving subsequent control, highlighting the importance of avoiding premature discontinuation of sirolimus.
- Sirolimus has allowed surgery or sclerotherapy to be performed in up to 20% of patients who were initially considered ineligible for such therapies.
- After stopping sirolimus, only one-third of patients restarted sirolimus, suggesting that the majority of patients do not need to remain on sirolimus indefinitely.
- Patients with the PIK3CA mutation may experience a faster response compared to those with the TIE2 mutation; they are also likely to experience a shorter relapse-free interval after sirolimus withdrawal. However, this needs further confirmation (21).

Sirolimus appears safe and easily manageable

Although adverse events (AEs) were reported in up to 85% of patients in the VASE trial, they were usually mild in severity, transient and easily manageable; the most frequent AEs included fatigue, mucositis, headache, diarrhoea and cutaneous rash (14, 16).

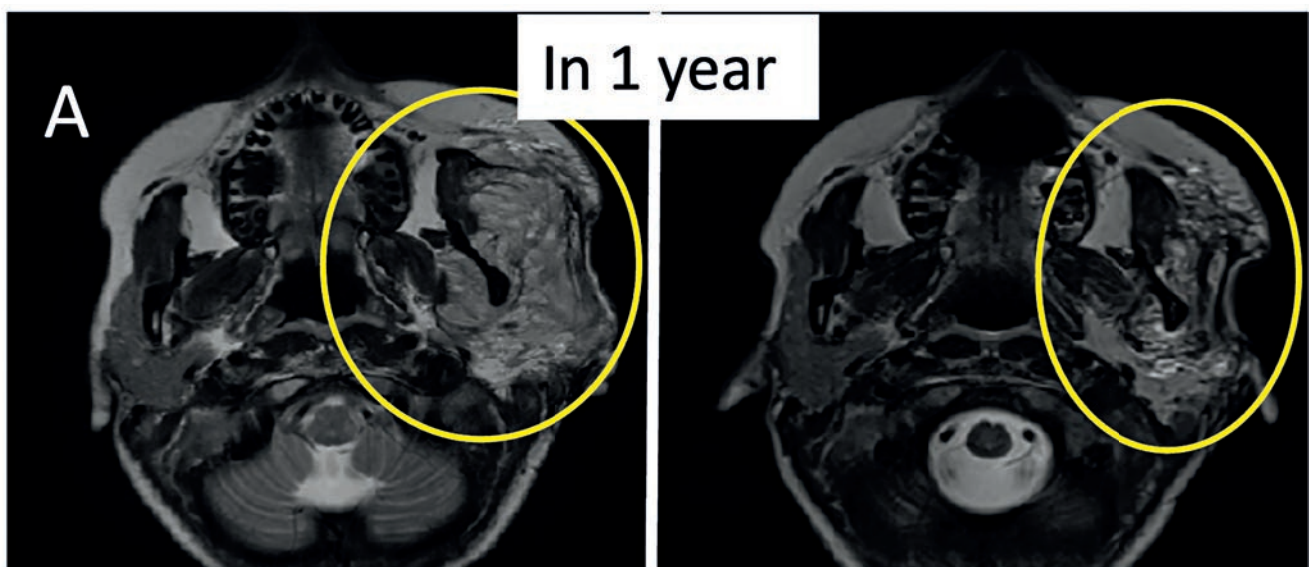


Figure 2: Evolution of venous malformations (VM) on sirolimus. (A) left cheek VM.

Interestingly, although rapamycin is historically described as an immunosuppressive agent, we did not observe any decrease in white blood cells or *Pneumocystis* infection (a bacterium commonly observed in immunosuppressed patients) or severe COVID complications. However, a close follow-up of patients treated with rapamycin is needed, mainly in patients with poor general condition, other comorbidities and/or very young children (< 3 months of age).

Preliminary results from VASE showed that pregnancy was also rapidly feasible after discontinuation of sirolimus,

decreasing the uncertainty regarding fertility with rapamycin (21). In December 2023, the VASCERN Vascular Anomalies Working Group issued a statement suggesting that, based on current evidence, the effects of sirolimus on gonadal function are generally small and reversible.

They emphasise the importance of specialists staying updated on emerging data and encourage them to continuously provide information to patients. (22).

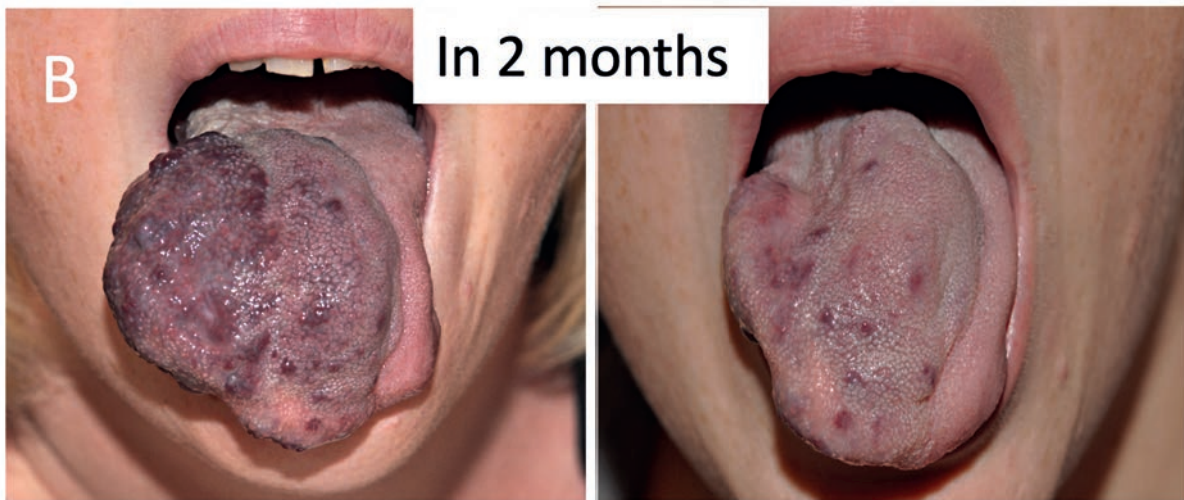

Figure 2: Evolution of venous malformations (VM) on sirolimus. (B) tongue VM.

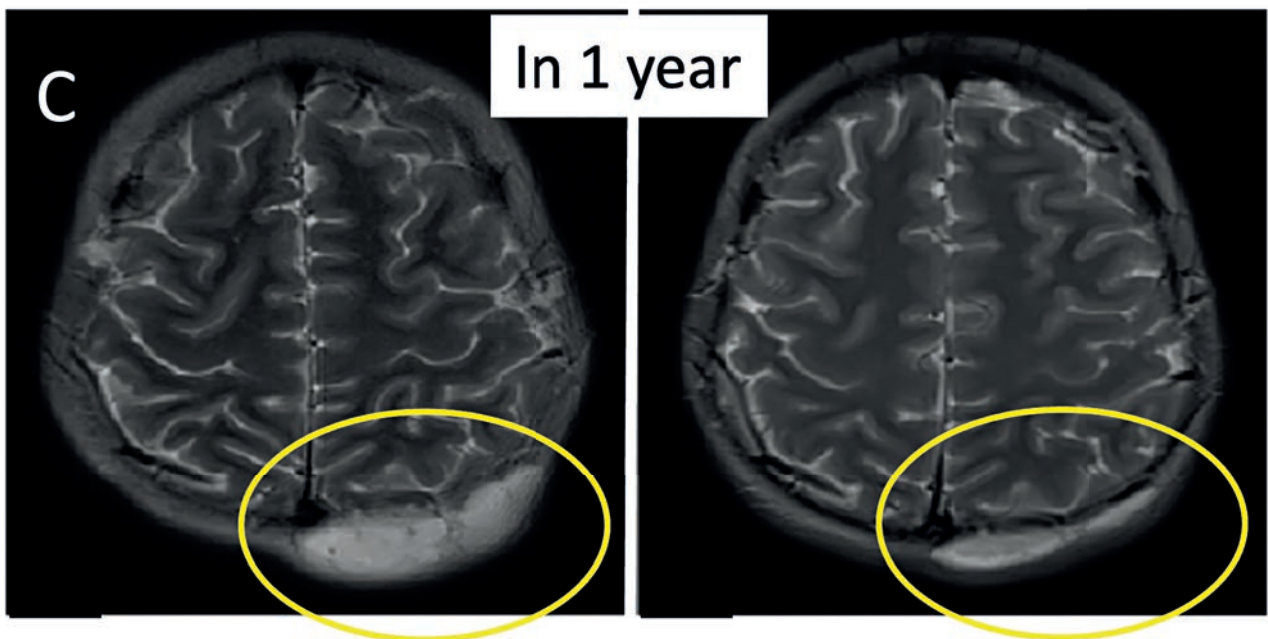


Figure 2: Evolution of venous malformations (VM) on sirolimus. (C) occipital VM.

Photo: Adapted from JCI insight 2023 (Seront E et al)

Photo: Adapted from JCI insight 2023 (Seront E et al)

Sirolimus efficient, as soon as possible?

In June 2023, we reported the successful management of a lymphatic malformation that was diagnosed in utero and treated with sirolimus taken orally by the mother during the pregnancy. This malformation, which was initially compressing the upper airway tract, decreased drastically, allowing for an uncomplicated delivery. Importantly, after a follow-up of 5.5 years, the child experienced a normal physical and neurological evolution (23).

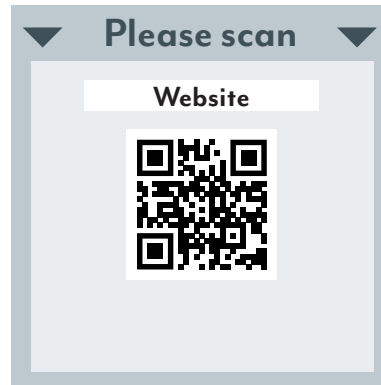
In conclusion

Through the VASE trial, sirolimus confirms its position as the new standard treatment in slow-flow vascular malformations, reducing symptoms and improving quality of life. Sirolimus allows further therapeutic options that were initially considered not feasible. Adverse events are usually mild and easily manageable. These results open the door to designing further therapeutic trials.

Source: Emmanuel Seront



Emmanuel Seront, MD, PhD



Emmanuel Seront, MD, PhD

Center for Vascular Anomalies
Cliniques universitaires St Luc
Avenue Hippocrate 10
1200 Bruxelles
(Belgique)
University of Louvain, Brussels, Belgium;
VASCERN VASCA European Reference Centre
www.saintluc.be



The authors:

Emmanuel Seront, MD, PhD^{1,2}, An Van Damme, MD, PhD^{1,3}, Miikka Vikkula, MD, PhD^{1,4}, Laurence Boon, MD, PhD^{1,5}

¹Center for Vascular Anomalies, Cliniques universitaires St Luc, University of Louvain, Brussels, Belgium; VASCERN VASCA European Reference Centre; ²Institut Roi Albert II, Department of Medical Oncology, Cliniques universitaires St Luc, University of Louvain, Brussels, Belgium; ³Institut Roi Albert II, Department of Pediatric Hematology & Oncology, Cliniques universitaires St Luc, University of Louvain, Brussels, Belgium; ⁴Human Molecular Genetics, de Duve Institute, University of Louvain, Brussels, Belgium; ⁵Division of Plastic Surgery, Cliniques universitaires St Luc, University of Louvain, Brussels, Belgium



<https://pubmed.ncbi.nlm.nih.gov/37937645/#:~:text=Sirolimus%20resulted%20in%20a%20clinical,resolved%20after%20treatment%20interruption%2Farrest>

References

- Wassef M, et al. Vascular anomalies classification: recommendations from the International Society for the Study of vascular anomalies. *Pediatrics*. 2015;136(1):e203–e214.
- Boon LM, et al. Pathogenesis of vascular anomalies. *Clin Plast Surg*. 2011;38(1):7–19.
- Mulliken JB, Glowacki J. Hemangiomas and vascular malformations in infants and children: a classification based on endothelial characteristics. *Plast Reconstr Surg*. 1982;69(3):412–422.
- Greene AK, et al. Vascular anomalies in 5621 patients : guidelines for referral. *J Pediatr Surg*. 2011;46(9):1784–1789.
- Cahill AM, et al. Pediatric vascular malformations: pathophysiology, diagnosis, and the role of interventional radiology. *Cardiovasc Intervent Radiol*. 2011;34(4):691–704.
- Boon LM, et al. [Medical and surgical treatment of venous malformations]. *Ann Chir Plast Esthet*. 2006;51(4–5):403–411.
- Queisser A, et al. Genetic basis and therapies for vascular anomalies. *Circ Res*. 2021;129(1):155–173.
- Van Damme A, et al. New and emerging targeted therapies for vascular malformations. *Am J Clin Dermatol*. 2020;21(5):657–668.
- Dekeuleneer V, et al. Theranostic advances in vascular malformations. *J Invest Dermatol*. 2020;140(4):756–763.
- Vikkula M, et al. Vascular dysmorphogenesis caused by an activating mutation in the receptor tyrosine kinase TIE2. *Cell*. 1996;87(7):1181–1190.
- Uebelhoer M, et al. Venous malformation– causative TIE2 mutations mediate an AKT–dependent decrease in PDGF. *Hum Mol Genet*. 2013;22(17):3438–3448.
- Limaye N, et al. Somatic mutations in angiopoietin receptor gene TEK cause solitary and multiple sporadic venous malformations. *Nat Genet*. 2009;41(1):118–124.
- Soblet J, et al. Variable somatic TIE2 mutations in half of sporadic venous malformations. *Mol Syndromol*. 2013;4(4):179–183.
- Boscolo E, et al. Rapamycin improves TIE2–mutated venous malformation in murine model and human subjects. *J Clin Invest*. 2015;125(9):3491–3504.
- Limaye N, et al. Somatic activating PIK3CA mutations cause venous malformation. *Am J Hum Genet*. 2015;97(6):914–921.
- Limaye N, et al. From germline towards somatic mutations in the pathophysiology of vascular anomalies. *Hum Mol Genet*. 2009;18(1):R65–R74.
- Hammer J, et al. Sirolimus is efficacious in treatment for extensive and/or complex slow-flow vascular malformations: a monocentric prospective phase II study. *Orphanet J Rare Dis*. 2018;13(1):191.
- Maruani A, et al. Sirolimus rapamycin for slow-flow malformations in children: the observational-phase randomized clinical PERFORMUS trial. *JAMA Dermatol*. 2021;157(11):1289–1298.
- Ji Y, et al. A prospective multicenter study of sirolimus for complicated vascular anomalies. *J Vasc Surg*. 2021;74(5):1673–1681.
- Adams DM et al. Efficacy and safety of sirolimus in the treatment of complicated vascular anomalies. *Pediatrics*. 2016;137(2):e20153257.
- Seront E, et al. Preliminary results of the European multicentric phase III trial regarding sirolimus in slow-flow vascular malformations. *JCI Insight*. 2023;8(21):e173095
- <https://vascern.eu/news/vascern-vascular-anomalies-working-group-publishes-new-consensus-statement-on-sirolimus-and-fertility/>
- Seront E, Biard J.M., Van Damme A, et al. A case report of sirolimus use in early fetal management of lymphatic malformation. *Nat Cardiovasc Res* 2, 595–599 (2023). <https://doi.org/10.1038/s44161-023-00280-4>

TESTIMONIAL

A Patient's Experience with AVM Treatment in the Czech Republic

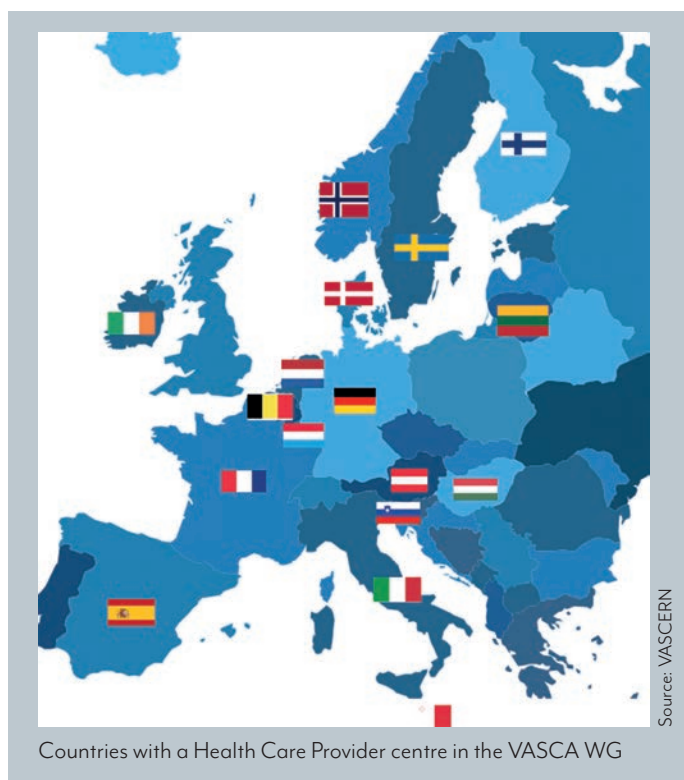Silvie Slívová

Arteriovenous malformations (AVMs) belong to a category of medical conditions known as vascular anomalies. Due to their infrequency in the population, they fall under the classification of rare diseases. In the Czech Republic, their prevalence is comparable to that in other European countries. Specifically focusing on AVMs of the head and neck, the condition is estimated to affect approximately 0.01% of patients. Considering the Czech Republic's population of 10 million, the incidence of this disease in our country is relatively low.

Given that AVMs can manifest in any part of the body, medical professionals from various fields may encounter this condition, though it may not be a common experience throughout their careers.

Consequently, it is not uncommon for many doctors to struggle with recognizing and diagnosing AVMs, and they may be uncertain about the appropriate referral procedures within specialised care.

Given that AVMs can manifest in any part of the body, medical professionals from various fields may encounter this condition, though it may not be a common experience throughout their careers.



Countries with a Health Care Provider centre in the VASCA WG

Despite substantial global progress in researching vascular anomalies over the last two decades, the lack of unified terminology and classification in the Czech Republic leads to frequent misdiagnoses, contributing to inadequate treatment and health complications. Some doctors continue to use the outdated code D18 (Hemangioma of any location) when classifying vascular malformations, which does not align with current classification standards.

However, there is positive news for Czech patients:

AVMinority, z.s., a patient organisation, has been operating for twelve years, providing support to AVM patients in finding or facilitating effective treatment throughout Europe.

In addition to endovascular embolotherapy of vascular malformations using Onyx or ethanol, which has been available for several years, biopsy procedures have been available in the Czech Republic since 2020 to determine the genetic mutation of a given vascular malformation, potentially leading to inclusion in the pilot phase of a clinical study involving pharmacological treatment with the drug Piqray (Alpelisib).

The system of care for patients with rare diseases in the Czech Republic is continually improving, with resources such as the consultation email help@vzacna-onemocneni.cz provided by the Czech Association for Rare Diseases (CAVO), facilitating communication between doctors and patients in complex cases.

Professionally guaranteed by the National Coordination Center for Rare Diseases, this service aims to direct patients to appropriate specialists who can assist.

Editor's note:

There are two doctors from the Czech Republic who have recently been in contact with the VASCA-WG.

Anxiety and Pain Management in Children During a Medical Procedure

Dr Lilian Vermeer*

Anxiety and pain during a medical procedure can be traumatic for children, even for the very young ones, and in some cases could even affect them later in life. In order to prevent pain and anxiety in children, especially in preparation for a medical procedure, it is important to build trust by using the right language, properly informing and preparing the patient and their parents, and even using techniques such as medical hypnosis and nitrous oxide.

Some research shows that repeated procedures against one's will or under duress, can cause a person more stress. Paediatrician Şükrü Genco from the OLVD hospital in the Netherlands says that more exposure to pain correlates with a lower pain threshold in children.

According to Elodie Mendels, a paediatric dermatologist at Erasmus MC in Rotterdam, pain, anxiety, and stress during medical procedures can be prevented in most cases. There are several techniques available to do this, but their effectiveness depends on using them in the right way, at the right time and in the right situation.

Parents can practise some of these techniques together with their children. It is also important to discuss expectations and avoid unexpected situations. Shifting focus through relaxation exercises, games, or digital distractions can further decrease anxiety and pain.

Nitrous oxide

One of the methods used to relieve pain and anxiety is administering nitrous oxide, and it supports the children into a peaceful and trusting place.

Medical hypnosis

Another non-medical method used is medical hypnosis, involving relaxation techniques and imagination similar to daydreaming or fantasising.

Focus language

This approach, deeply rooted in relaxation and distraction techniques, focuses on positive reassurance and using the right words to redirect the patient's attention. Think about taking the negative undertones and words from the conversation.

Mirroring the patient's non-verbal communication


By mirroring the patient's body language, the patient unconsciously can feel more understood and comfortable.

*This is a summary from an article composed by Dr Lilian Vermeer (Editor CMTC-OVM) based on:

1. Focus language: a tool for healthcare providers and parents. Heel de Huid, magazine about skin and hair conditions (NVDV, Utrecht, the Netherlands), page 34, December 2021,
2. On the breach for a child-oriented approach, Endocrinologiekant 'Het Relas', 10 Augustus 2018
3. Potential impact of medical intervention on very young children, website CMTC.nl, Marianne Versaavel, 2021

More information can be found in the CMTC OVM website.

○ <https://www.cmtc.nl/en/>



Subscribe to the newsletter for the latest updates on rare vascular diseases from VASCERN.

VASCA-WG Healthcare Providers (HCP) Full members

Prof. Miikka VIKKULA	Clinical Geneticist	Cliniques Universitaires Saint-Luc BELGIUM ○ www.saintluc.be
Prof. Laurence M. BOON	Plastic and Reconstructive Surgeon	
Dr. Thomas HJULER	Physician	Rigshospitalet - University of Copenhagen DENMARK ○ www.ku.dk/english
Dr. Mikkel KALTOFT	Otorhinolaryngologist	
Pr. Kristiina KYRKLUND	Pediatric Surgeon	Helsinki University Hospital FINLAND ○ www.hus.fi/en
Dr. Jukka TOLONEN	Internal Medicine Specialist	
Dr. Annouk Anne BISSORFF	Neuroradiologist	AP-HP Hôpital Lariboisiere FRANCE ○ https://hopital-lariboisiere.aphp.fr/
Dr. Olivia BOCCARA PERRIN	Dermatologist/Venerologist	
Dr. Friedrich KAPP	Pediatric Hematologist/Oncologist	Medical Center - University of Freiburg GERMANY ○ www.uniklinik-freiburg.de/en
Dr. Annegret HOLM	Pediatric Hematologist/Oncologist	
Prof. Alan IRVINE	Professor of Dermatology	Children's Health Ireland IRLAND ○ www.olchc.ie
Dr. Veronika DVORAKOVA	Consultant Dermatologist	
Dr. Andrea DIOCIAUTI	Dermatologist	Bambino Gesù Children's Hospital ITALY ○ www.ospedalebambinogesu.it
Dr. May EL HACHEM	Dermatologist	
Dr. Birutė VAIŠNYTĖ	Vascular Surgeon	Vilniaus Universiteto ligoninė Santaros Klinikos LITHUANIA ○ www.santa.lt
Dr. Darius PALIONIS	Radiologist	
Prof. Leo SCHULTZE KOOL	Interventional Radiologist	Radboud University Medical Center NETHERLANDS ○ www.radboudumc.nl/patientenzorg
Dr. Carine VAN DER VLEUTEN	Dermatologist	
Dr. Rune ANDERSEN	Radiologist	Oslo University Hospital NORWAY ○ www.oslo-universitetssykehus.no
Dr. Sigurd BERGER	Radiologist	
Dr. Maria BOM SUCESSO	Pediatric Oncologist	Centro Hospitalar Universitário de São João PORTUGAL ○ www.portal-chsj.min-saude.pt
Dr. Antonio Miguel MADUREIRA	Radiologist	
Dr. Eulalia BASELGA TORRES	Pediatric Dermatologist	SJD (Sant Joan De Déu) Barcelona Children's Hospital SPAIN ○ www.sjdhospitalbarcelona.org/en
Dr. Miguel BEJARANO SERRANO	Pediatric Surgeon	
Dr. Nader GHAFFARPOUR	Pediatric Surgeon	Karolinska University Hospital SWEDEN ○ www.karolinska.se
Dr. Sofia FRISK	Clinical Geneticist	

Affiliated Partner

Dr. Paolo GASPARELLA	Pediatric Surgeon	University Hospital Graz AUSTRIA ○ www.klinikum-graz.at
Prof. Emir HAXHIJA	Pediatric Surgeon	

VASCERN Coordination (FRANCE)

Assistance Publique-Hôpitaux de Paris, Hôpital Bichat–Claude Bernard | 46 rue Henri Huchard – 75018 Paris


Prof. Guillaume JONDEAU	VASCERN Coordinator - Cardiologist	VASCA Working Group built upon Multidisciplinary Centres of Excellence for Vascular Anomalies ○ www.vascern.eu/group/vascular-anomalies 
Julie HALLAC	VASCERN Project Manager	
Treasure UDECHUKWU	VASCERN Communications Project Officer	
Gloria SOMALO BARRANCO	VASCERN Scientific Project Officer	
Yaël GLIN	VASCERN Project Officer	
Ibrahim DONMEZ	VASCERN IT Helpdesk & End User Support Specialist	



Photo: AdobeStock_73868450



www.vascern.eu



European Reference Network

VASCERN

Gathering the best expertise in Europe to provide accessible cross-border healthcare to patients with rare vascular diseases



European Patient Advocacy Group

VASCA



HEVAS



BUNDESVERBAND
Angeborene
Gefäßbildungen e.V.
Eckstr. 10 • 40225 Düsseldorf • EGV



LGD Alliance Europe
For Complex Lymphatic Anomalies



ANLINA
Asociación Nacional
de Doenças Linfáticas
National Association of Patients
of Lymphatic Disorders



Vascapa



cmtcvm



AVMINORITY